

# Interdisciplinary Management of Single-Tooth Implants

Frank M. Spear, David M. Mathews, and Vincent G. Kokich

**Orthodontists treat many patients who are missing maxillary lateral incisors and/or mandibular second premolars. In the past, if the canines could not be substituted for lateral incisors, conventional full-coverage bridges were the common restoration. Recently, resin-bonded Maryland bridges became a popular substitute for conventional bridges to avoid crowns on the nonrestored abutments. However, resin-bonded bridges have a poor long-term prognosis for retention, lasting on average about 10 years. Since implants were introduced into dentistry by Swedish researchers in the mid-1980s, they have become a promising substitute for conventional or resin-bonded bridges. However, to successfully place and restore single-tooth implants in young orthodontic patients several questions must be answered. This article will discuss the many interdisciplinary issues that are involved in placing and restoring single-tooth implants in orthodontic patients. (Semin Orthod 1997; 3:45-72.) Copyright © 1997 by W.B. Saunders Company**

Orthodontists treat many patients who have missing teeth. Some of these individuals are adults who have lost teeth because of caries or periodontal disease. However, many partially edentulous orthodontic patients have congenitally missing maxillary lateral incisor and mandibular second premolar teeth. In the past, if space closure was not an orthodontic treatment option, restoration of the edentulous space was the alternative. Previous options for restoring edentulous spaces have either been conventional full-coverage bridges or resin-bonded Maryland bridges. Today, most young patients are caries-free. Therefore, full-coverage bridges are inappropriate. Resin-bonded bridges have a high failure rate. Therefore, most dentists as well as patients are considering single-tooth implants to replace congenitally missing permanent teeth. Implants require interdisciplinary interaction between orthodontist, surgeon, and restorative dentist. This article will discuss the critical issues

that must be addressed to achieve an optimal result with single-tooth implants.

## Space Requirement

### Maxillary Lateral Incisors

If a patient is congenitally missing one maxillary lateral incisor, the amount of space for the implant and crown is determined by the contralateral lateral incisor. However, in some patients, the existing lateral incisor may be peg-shaped. In other situations, both lateral incisors are congenitally absent. In the latter instance what then determines the amount of space for the implant and crown? The amount of space is determined by two factors: esthetics and occlusion.

An esthetic relationship exists between the size of the maxillary central and lateral incisor teeth. This size ratio has been called the "golden proportion." Ideally, the maxillary lateral incisor should be about two-thirds the width of the central incisor.<sup>1</sup> Most central incisors are between 8 and 10 mm wide. If the central incisor is 8 mm in width, then the lateral incisor should be 5.5 mm wide. If the central incisor is 9 mm in width, then the width of the lateral incisor should be 6 mm. If the central incisor is 10 mm wide then the lateral incisor should be 6.7 mm

*From the Department of Orthodontics, School of Dentistry, University of Washington, Seattle, WA.*

*Address correspondence to Vincent G. Kokich, DDS, MSD, Department of Orthodontics, School of Dentistry, University of Washington, Seattle, WA 98195.*

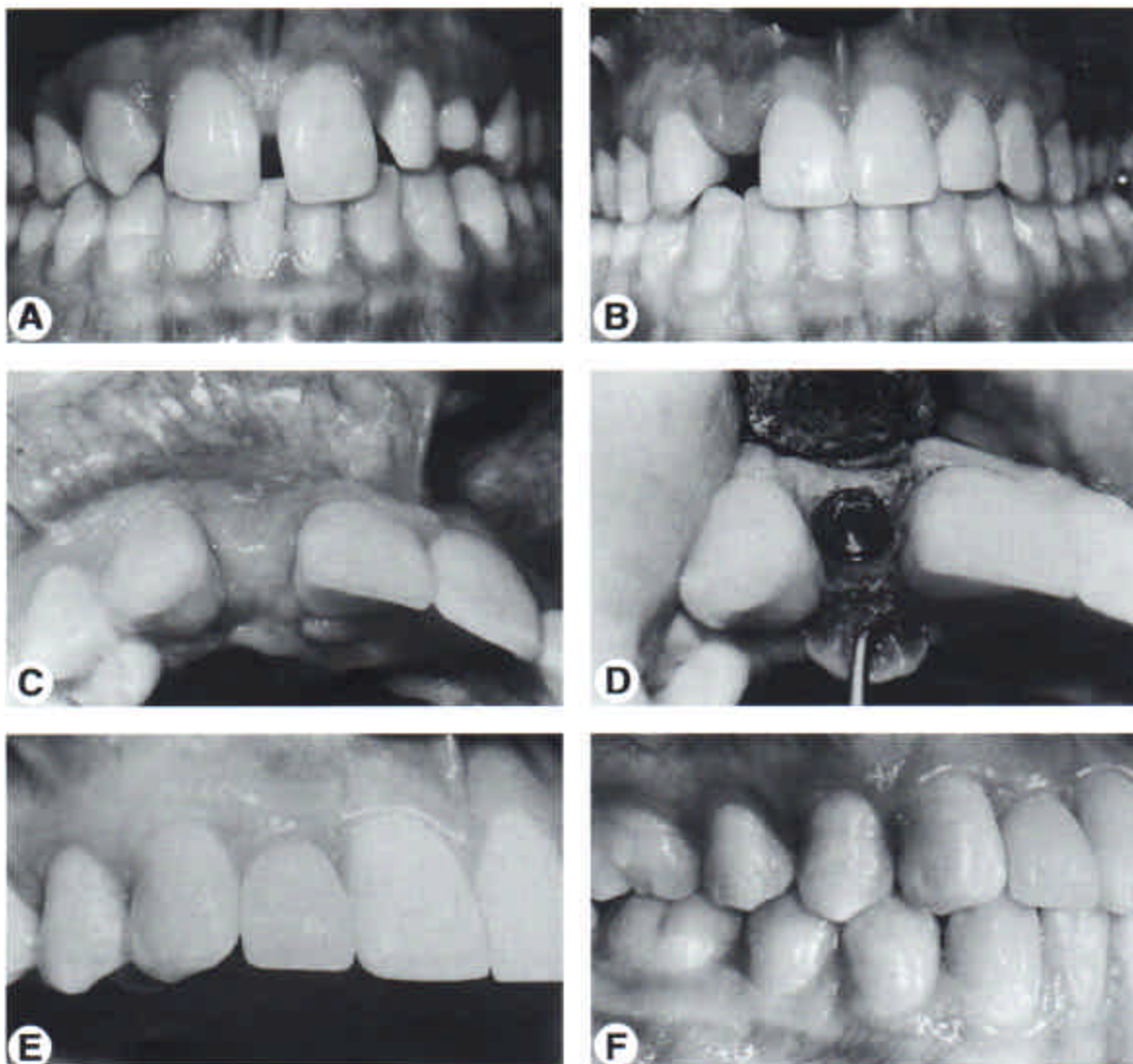
*Copyright © 1997 by W.B. Saunders Company  
1073-8746/97/0301-0005\$5.00/0*

wide. Therefore, the width of most lateral incisors will range from 5.5 to 6.7 mm.

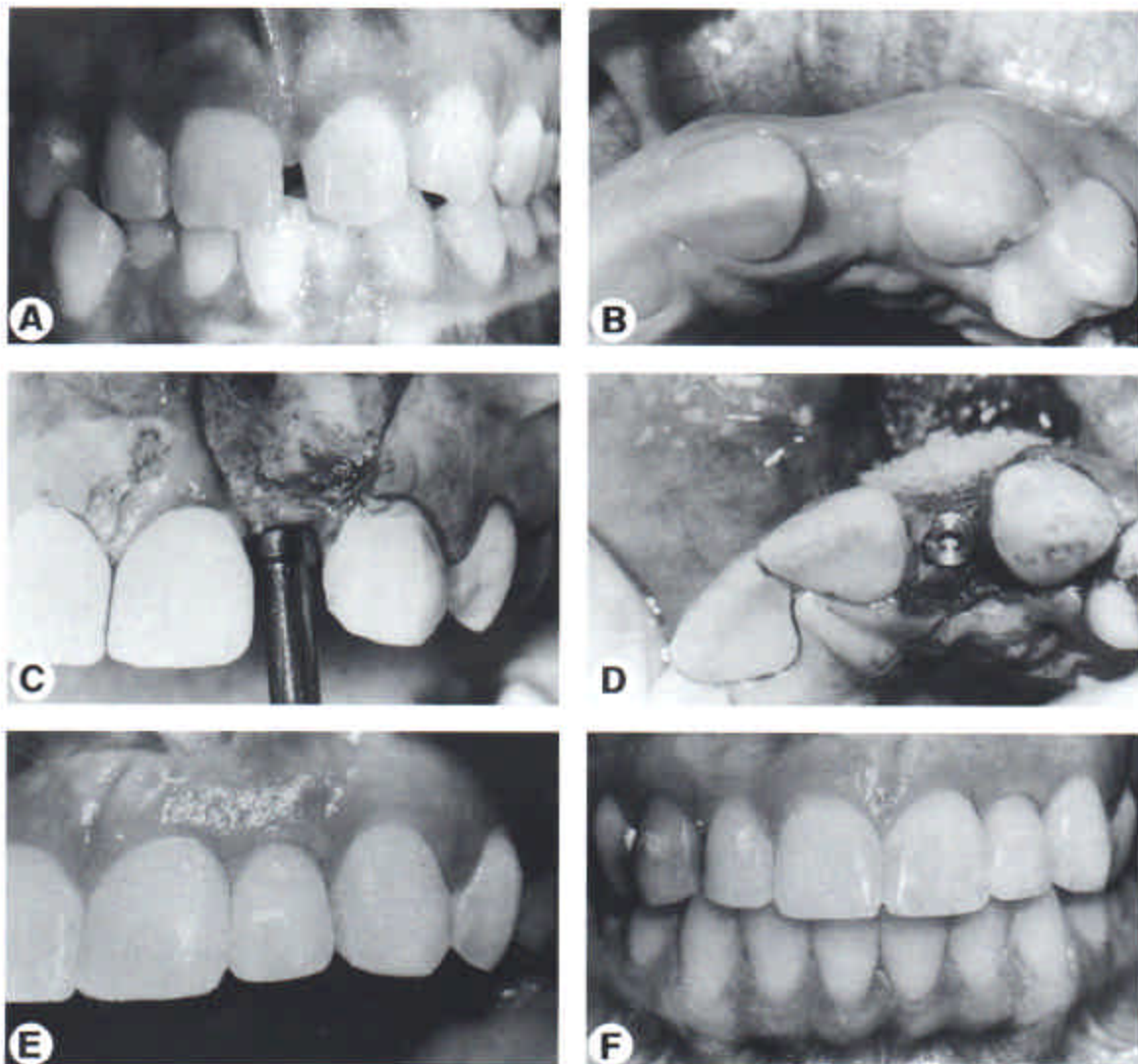
In some situations, the orthodontist may create less than ideal width for the lateral incisor implant and crown because of occlusal considerations (Figs 1 and 2). The orthodontist should be assessing the posterior intercuspation, as well as the appropriate amount of overbite and overjet. If the correct occlusion has been achieved, and the space for the implant crown is too narrow, the orthodontist should remove enamel inter-

proximally from the central incisors and canines to provide additional width for the lateral incisor crown.

The traditional width of an implant is 3.75 mm. The platform on the implant is about 4.0 mm wide. This measurement is important because the platform must fit interproximally between the central incisor and canine at the crest of the alveolar ridge. If the orthodontist has created 5.5 mm of space for the lateral incisor, and the platform of the implant is 4 mm wide,



**Figure 1.** This patient was congenitally missing the maxillary right lateral incisor (A). During orthodontic treatment, space was opened for an implant to replace the maxillary right lateral incisor (B). To match the size of the left lateral incisor, the space was 5.5 mm (C). A 3.75 mm implant was placed between the central incisor and canine (D). When a wider implant is placed in a narrow space, the amount of space for the papilla is reduced. As a result, the papilla is positioned more apically (E and F).



**Figure 2.** This patient was congenitally missing the maxillary left lateral incisor (A). A 5.5 mm space was created for the left lateral incisor to match the size of the existing right lateral (B). In this narrow space, a 2.9 mm implant was placed (C and D). With the narrower implant, more space remained between the implant and the adjacent tooth and permitted a more esthetic regeneration of natural papillae around the implant crown (E and F).

less than 1 mm space will remain between the implant and the adjacent central incisor and canine teeth (Fig 1). Previous articles have suggested that the space between the implant and the adjacent tooth should be at least 1 mm for proper healing and to ensure adequate space for the development of a papilla. In narrower spaces, smaller implants could be used to provide additional space between the implant and the adjacent teeth (Fig 2). If the size of the lateral incisor is 6.7 mm, the traditional 3.75 mm implant will

provide more than 1 mm of space between the platform and the adjacent teeth.

Another important area that is often overlooked during orthodontic finishing is the space between the roots of the central incisor and canine teeth. If space has been created for the implant by moving the central incisor and canine apart, the roots may have moved into closer proximity. In the latter situation, there may be inadequate space to fit the implant between the apices of the central incisor and canine teeth.

During finishing, the orthodontist must move the apices of the teeth apart to provide adequate space for the surgeon to position the implant between the roots of the teeth.

#### Mandibular Premolars

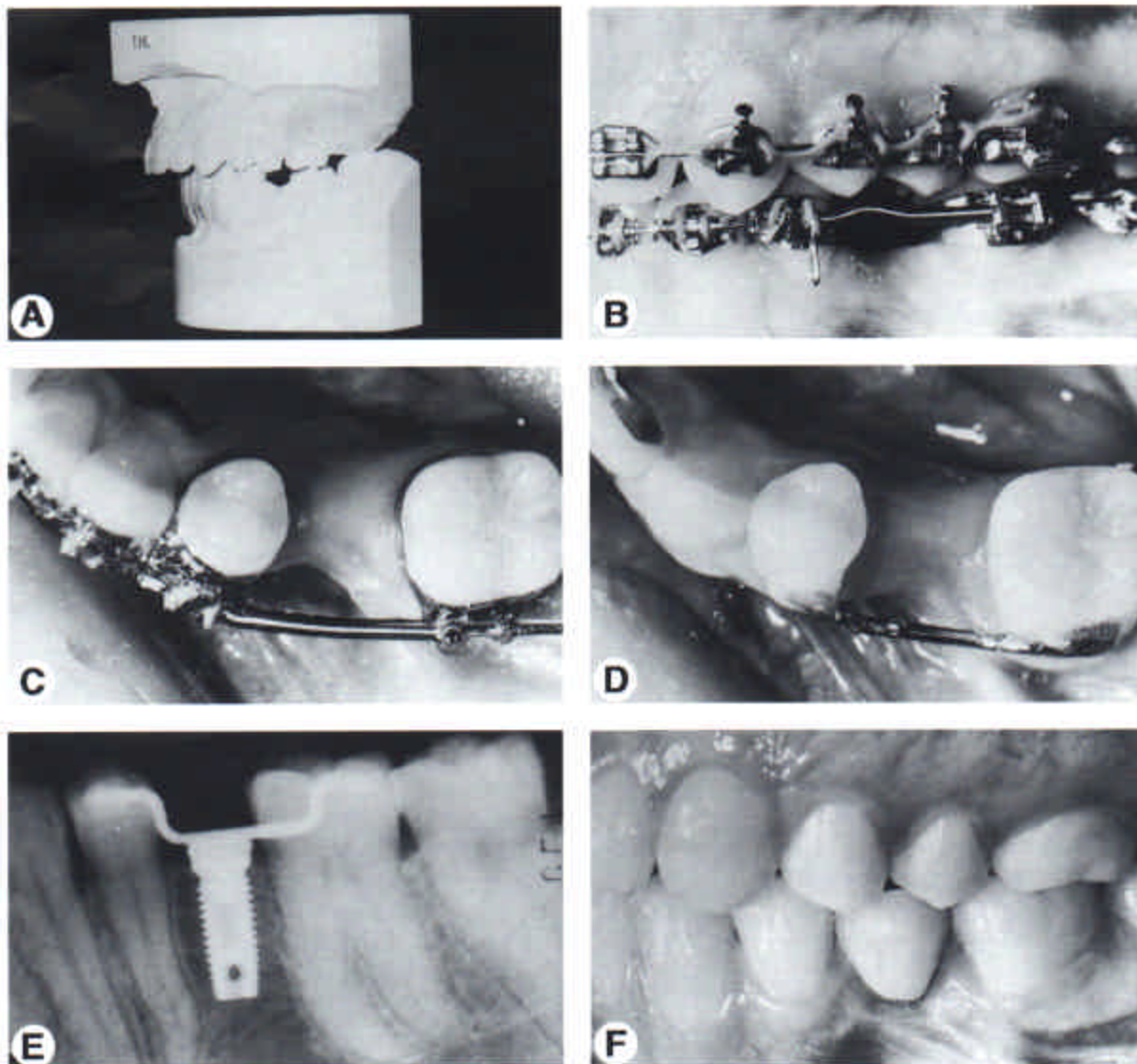
Most mandibular premolars are between 7 and 8 mm wide. If the premolar is congenitally absent, the space created for the implant and crown will be determined primarily by the posterior occlusion or intercuspation (Fig 3). If the edentulous space is 7.5 mm, and the implant has a 4 mm platform, greater than 1 mm of space will remain

between the implant and the adjacent teeth. This amount of space is sufficient to permit proper bone-fill around the implant and leave adequate space for a papilla between the implant crown and the adjacent teeth.

#### Timing of Placement

##### Adolescent Patients

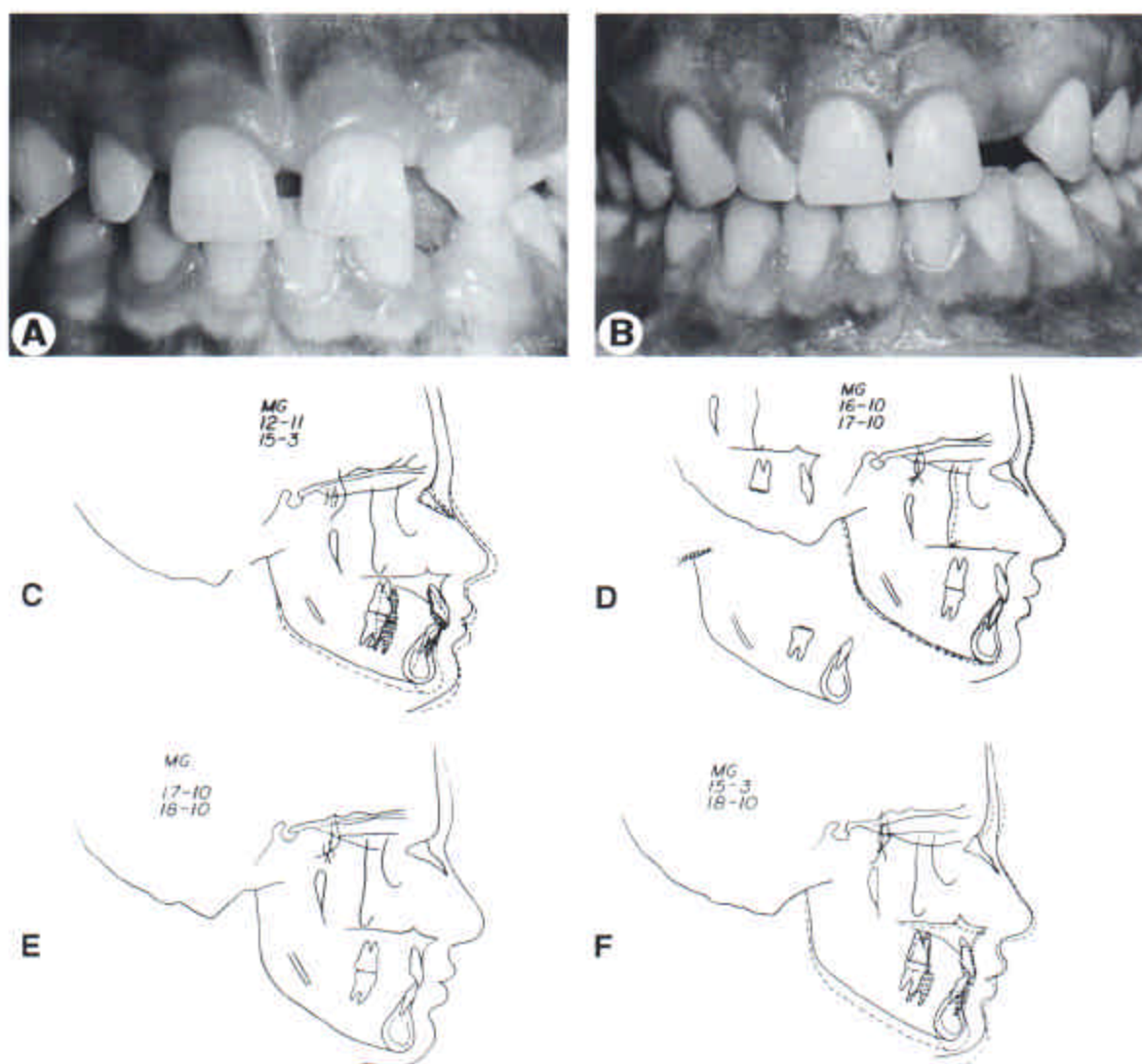
Most orthodontic patients are about 14 to 15 years of age at the end of orthodontic treatment. If a male adolescent completes his orthodontic treatment at 15 years of age, and a maxillary



**Figure 3.** This patient was congenitally missing the mandibular second premolar (A). Space was opened for an implant between the first premolar and first molar (B and C). After orthodontic treatment (D) an implant was placed in the second premolar site (E) and restored with a porcelain crown (F).

lateral incisor is congenitally absent, at what time can the implant be placed? If the implant is placed and restored too early, relative to the patient's tooth eruption, the reaction of the implant will be similar to that of an ankylosed tooth. The adjacent teeth may erupt, and a discrepancy will be created between the gingival margins of the implant and the natural teeth.<sup>2,3</sup> In a patient with a high lip line, this could be esthetically unacceptable. For these reasons patients should have completed the majority of their tooth eruption before the placement of an implant.

Teeth erupt in response to growth. The question that the orthodontist must answer is whether or not the patient has completed the majority of their facial growth. A hand-wrist radiograph is inappropriate for the latter assessment because it is not specific enough for each patient. The best method of evaluating the completion of facial growth is by superimposing sequential cephalometric radiographs (Fig 4). Most boys have not completed their facial growth until the late teenage years. A 14- or 15-year-old boy may not have gone through their adolescent growth spurt. It is advisable to wait until an adolescent male has



**Figure 4.** Orthodontic treatment was begun on this patient at 12 years, 11 months of age and completed at 15 years, 3 months of age (A and B). Over the time of treatment, the patient grew significantly (C). Sequential cephalometric superimpositions made after orthodontic treatment (D, E and F) indicated that the patient had not completed facial growth and was therefore not ready for implant placement until 18 years, 10 months of age.

completed growth in height. At that point, a cephalometric radiograph should be taken. Another radiograph should be taken at least 6 months to a year later. If these radiographs are superimposed and there are no changes in vertical facial height (nasion to menton), then this indicates that most of the facial growth has been completed. If an implant is placed at that time, significant eruption of adjacent teeth would not be expected.

In girls, the growth of the face is often completed by 15 years of age. Therefore, it may be possible to place implants for congenitally missing teeth as early as 15 years in girls without the risk of eruption of adjacent teeth. However, sequential cephalometric radiographs should be compared to verify that vertical facial growth has ceased.

#### Adults

Implants can be placed in adult patients at any time after the edentulous space has been opened. In most situations, it is easier to wait until the appliances have been removed before placing the implant. However, in some patients, it may be advisable to place an implant immediately after extraction of a fractured or hopeless tooth (Fig 5). For example, if a maxillary lateral incisor has a vertical fracture or an untreatable periodontal defect and must be extracted, the implant can be placed immediately (Fig 5). In these situations, if orthodontics has been initiated to align adjacent teeth, the extraction of the hopeless tooth, and the placement of the implant may be accomplished during the orthodontic treatment to ensure that the alveolar ridge does not resorb. Final restoration of the implant may be delayed until after the orthodontic appliances have been removed.

#### Changes in Ridge Width

If an adolescent male completes orthodontic treatment at age 15, and if an implant replacing a lateral incisor will not be placed until age 20, the buccolingual thickness of the alveolar ridge could decrease over that period of time. Significant narrowing of the ridge could jeopardize placement of an implant. Previous research has shown that after tooth extraction, the maxillary anterior buccolingual width is reduced by 23% in the first 6 months (Fig 6). After 5 years an

additional 11% loss in ridge width occurs. Therefore, after tooth extraction, the ridge width will narrow by approximately 34% over 5 years.<sup>4</sup>

When the maxillary lateral incisor is congenitally absent, the canine may erupt adjacent to the central incisor. As the permanent canine is moved distally to create space for a lateral incisor implant, an alveolar ridge is created (Fig 7). What happens to the buccolingual width of this bone over time? This question was addressed in a recent study.<sup>5</sup>

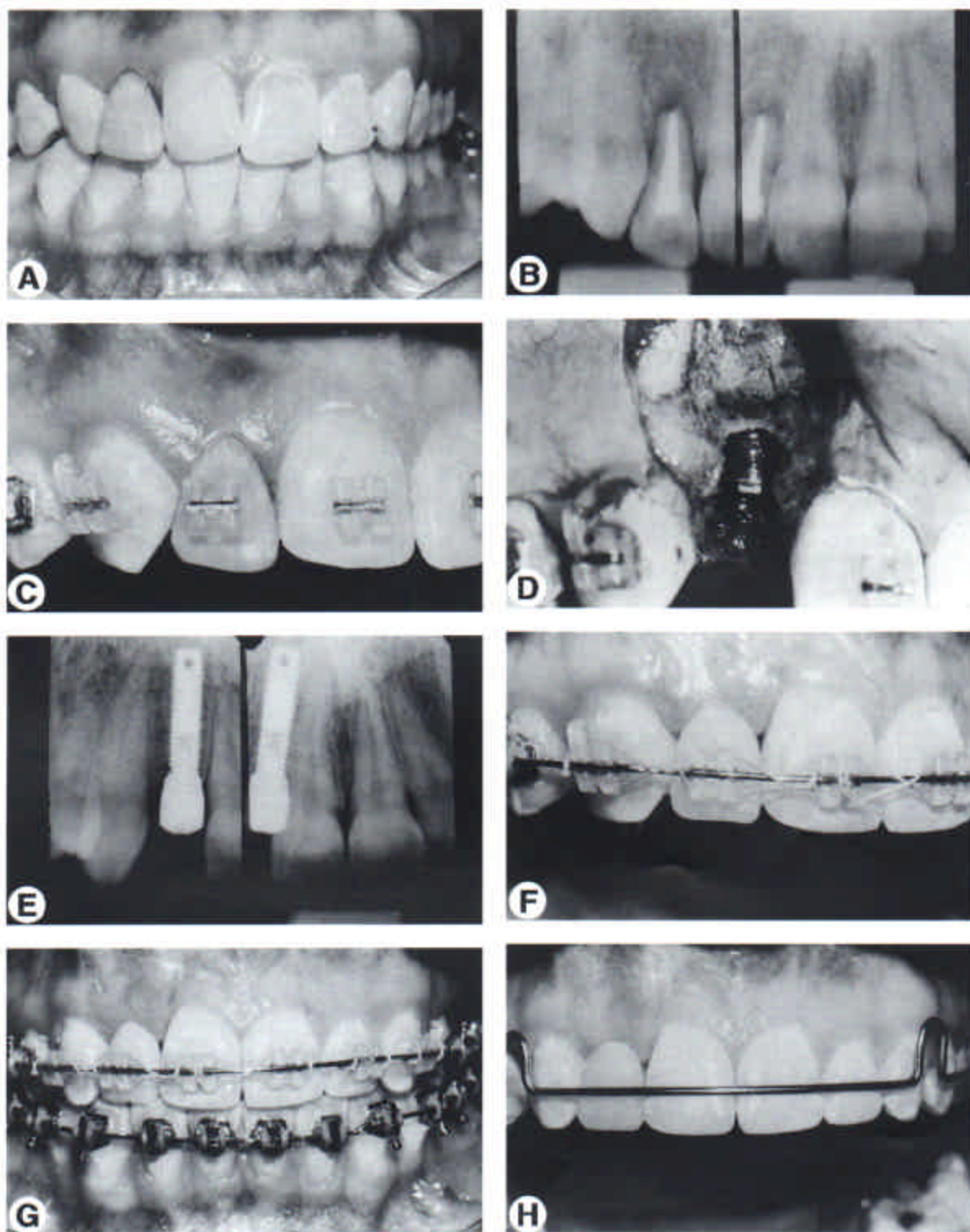
A sample of 20 patients with congenitally missing lateral incisors were evaluated at the end of orthodontic treatment and at an average of 4 years after appliance removal. All patients were congenitally missing at least one lateral incisor tooth. Space was created for restorations in all edentulous sites. Tomograms through the edentulous ridge were made at the 4-year recall. Maxillary dental casts were sectioned across the edentulous ridge. Comparison of posttreatment and long-term measurements of the dental casts and tomograms revealed the amount of change that occurred across these edentulous ridges with time. The amount of bone loss in this sample was less than 1% over 4 years. If teeth are extracted, the ridge will narrow by 34%.<sup>4</sup> If the edentulous alveolar ridge has been created by the orthodontic separation of two teeth, little resorptive change will occur over time.

Based on this information, the orthodontist should allow the permanent canines to erupt mesially if the maxillary lateral incisors are congenitally absent (Fig 8). As the canines are moved distally, an edentulous ridge will be created. Over time, this ridge will not resorb as much as a ridge resorbs following tooth extraction.

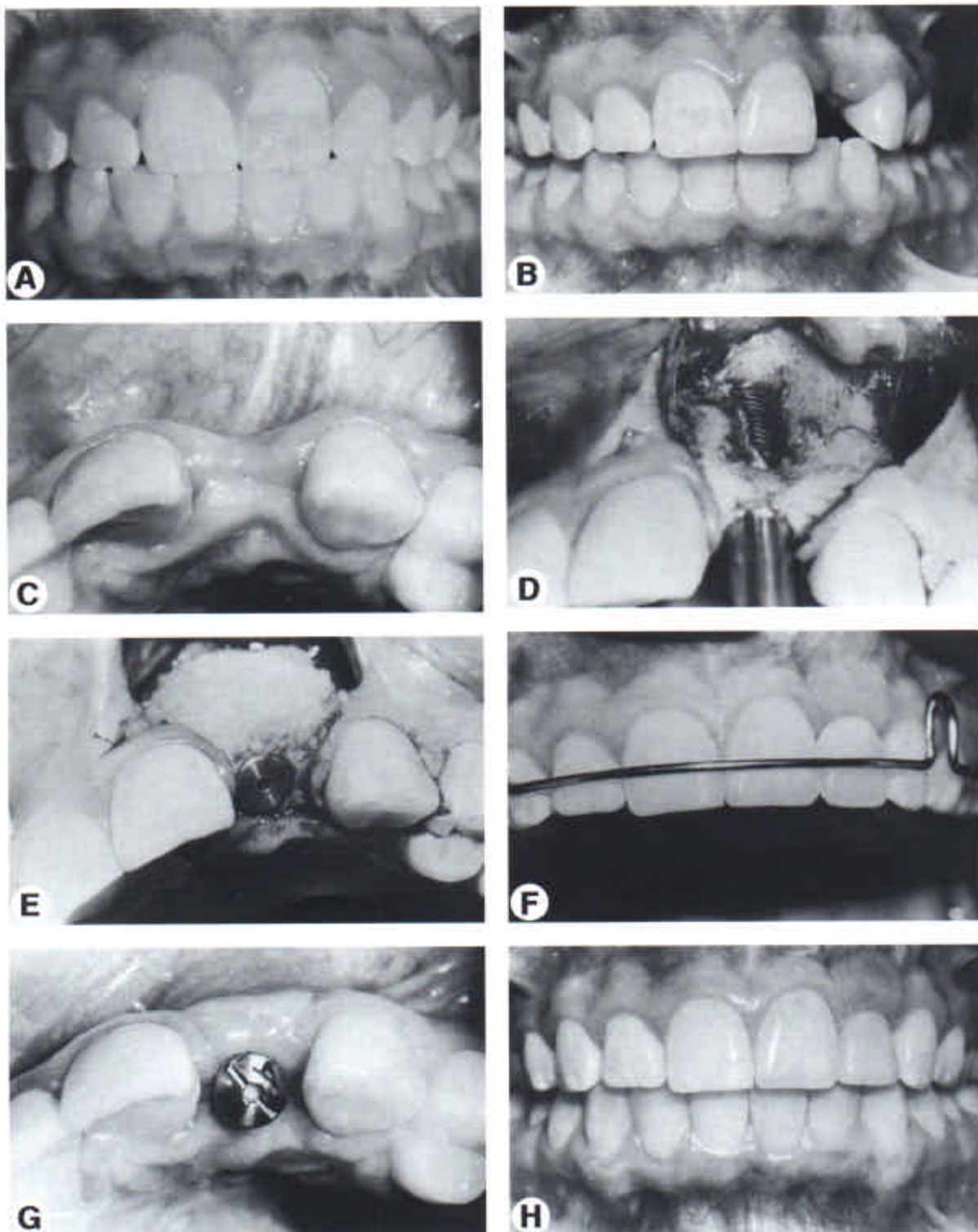
#### Timing Extraction of Primary Teeth

##### Maxillary Arch

If the maxillary lateral incisor tooth is congenitally absent and the maxillary canine has erupted distal to the central incisor, the primary canine may still be present distal to the permanent canine. When should the primary canine be extracted (Fig 9)? If it is extracted too early, the ridge will undergo resorption and the buccolingual thickness will decrease. However, the permanent canine must be moved into the primary canine space. In this situation, the primary canine should be extracted just before moving the

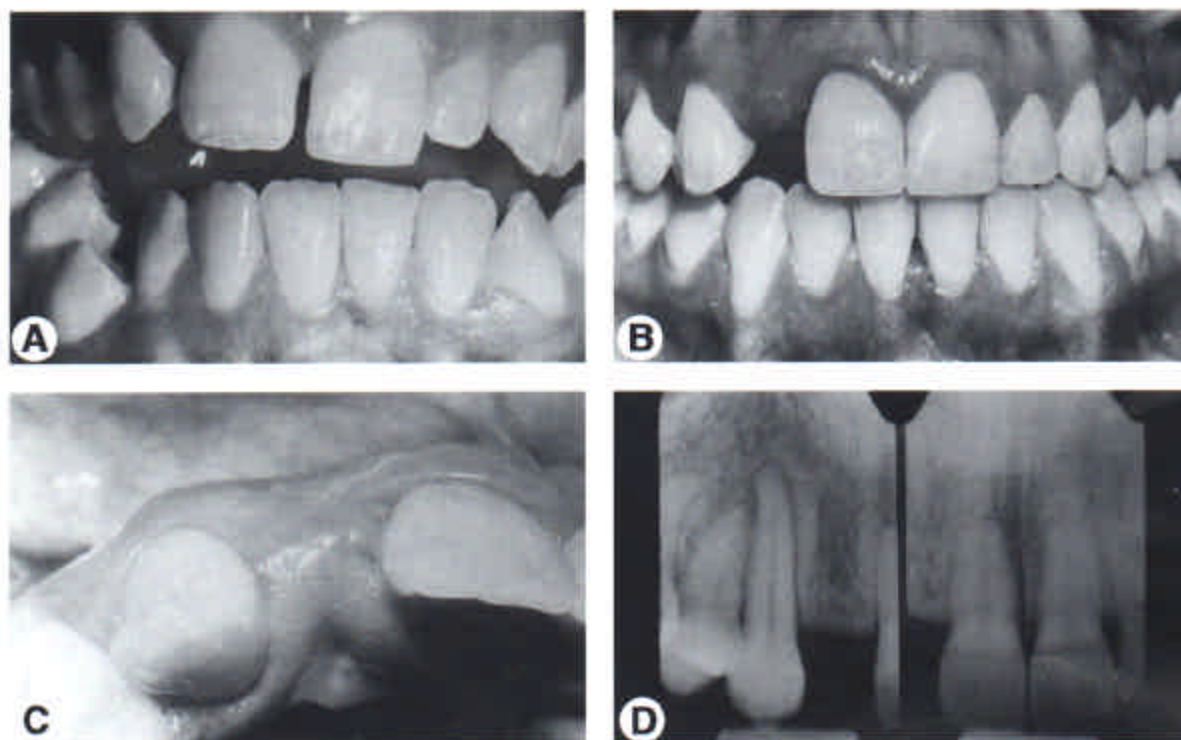


**Figure 5.** This patient's maxillary right lateral incisor had an unresolvable periodontal defect (A and B). The teeth were aligned (C), the lateral was extracted, and an implant was placed immediately (D). A plastic tooth was used to hold the space after implant placement (E-H).



**Figure 6.** After orthodontic treatment (A), this patient avulsed the maxillary left lateral incisor (B and C). Although the ridge had narrowed because of the loss of the tooth, an implant was placed (D and E) and the labial was augmented with bone. After uncovering, a retainer (F) was used to permit healing of the soft tissue around the healing abutment (G). After the tissue had healed adequately, the final restoration was placed (H).





**Figure 7.** This patient was congenitally missing the maxillary right lateral incisor (A). The canine and central incisor had erupted adjacent to one another. During orthodontics, the central and canine were moved apart (B). As the teeth were separated, the alveolar ridge was created for placement of an implant (C and D).

permanent canine distally. This will ensure that significant resorption of the ridge will not occur.

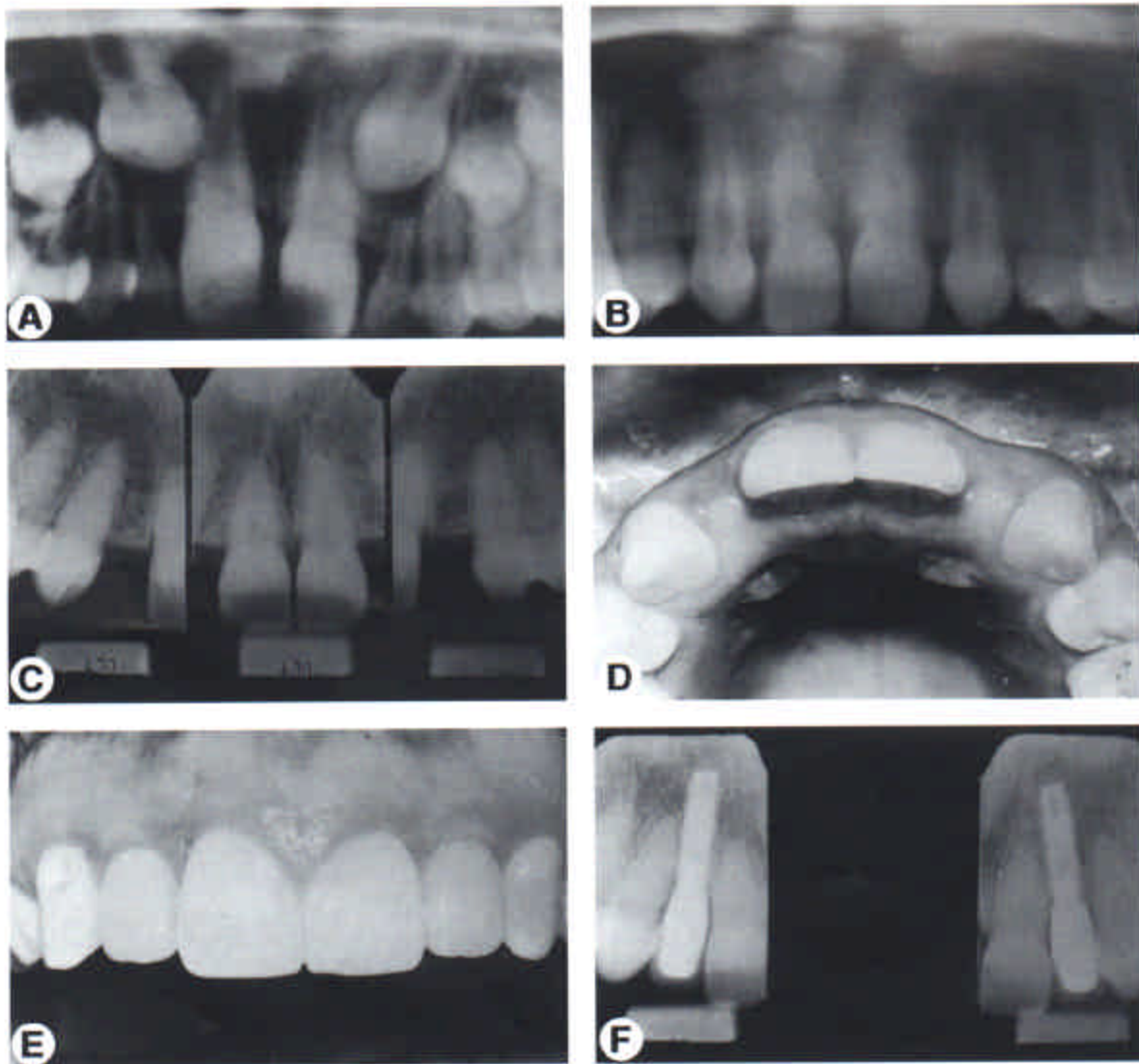
#### Mandibular Arch

If the mandibular second premolars are congenitally absent, the primary second molars may still be present in the dental arch. Should these teeth be extracted early to permit placement of an implant? If the primary molar is extracted, the ridge thickness will decrease by about 30%.<sup>6</sup> There is another alternative. If the primary second molar is not ankylosed, it can be reduced in width by interproximal removal of enamel and dentin (Fig 10). Mandibular primary second molars are approximately 10 to 12 mm wide. By reducing the mesial-distal width, the tooth can be narrowed to about 8 mm. By retaining the primary second molar, but reducing its width, the buccolingual thickness of the alveolus will be maintained. When the patient has completed growth, the primary molar may be extracted, and an implant can be placed. By retaining the primary molar, the width of the alveolus will be

maintained and placement of the implant may be simpler and more predictable.

If the mandibular second premolar is congenitally absent, and the primary molar is ankylosed, it will be progressively submerged as the adjacent teeth erupt. This will create a vertical defect between the adjacent first premolar and first molar that could complicate the placement of an implant at a later time. In this situation, the ankylosed primary molar should be extracted early. Studies have shown that the alveolar crest will follow the adjacent first molar and first premolar as they erupt. This will prevent a vertical defect in the edentulous ridge. If a 12- or 13-year-old girl has an ankylosed primary second molar, it may not need to be extracted. A girl may have limited growth of the mandible remaining and, therefore, the adjacent teeth will have reduced eruption potential.

If a primary molar is extracted at a young age, and the buccolingual thickness of the ridge decreases, the ridge may need augmentation before placing an implant. In some situations, orthodontics can be used to augment the ridge.



**Figure 8.** If maxillary lateral incisors are congenitally absent (A), it is advantageous to allow the canines to erupt adjacent to the central incisors (B). As the canines are moved distally (C), the edentulous ridge is created (D). This will provide an adequate ridge for implants to be placed and restored (E and F).

In other cases, bone grafting may be necessary to build up a ridge before placing the implant.

## Orthodontic Ridge Augmentation

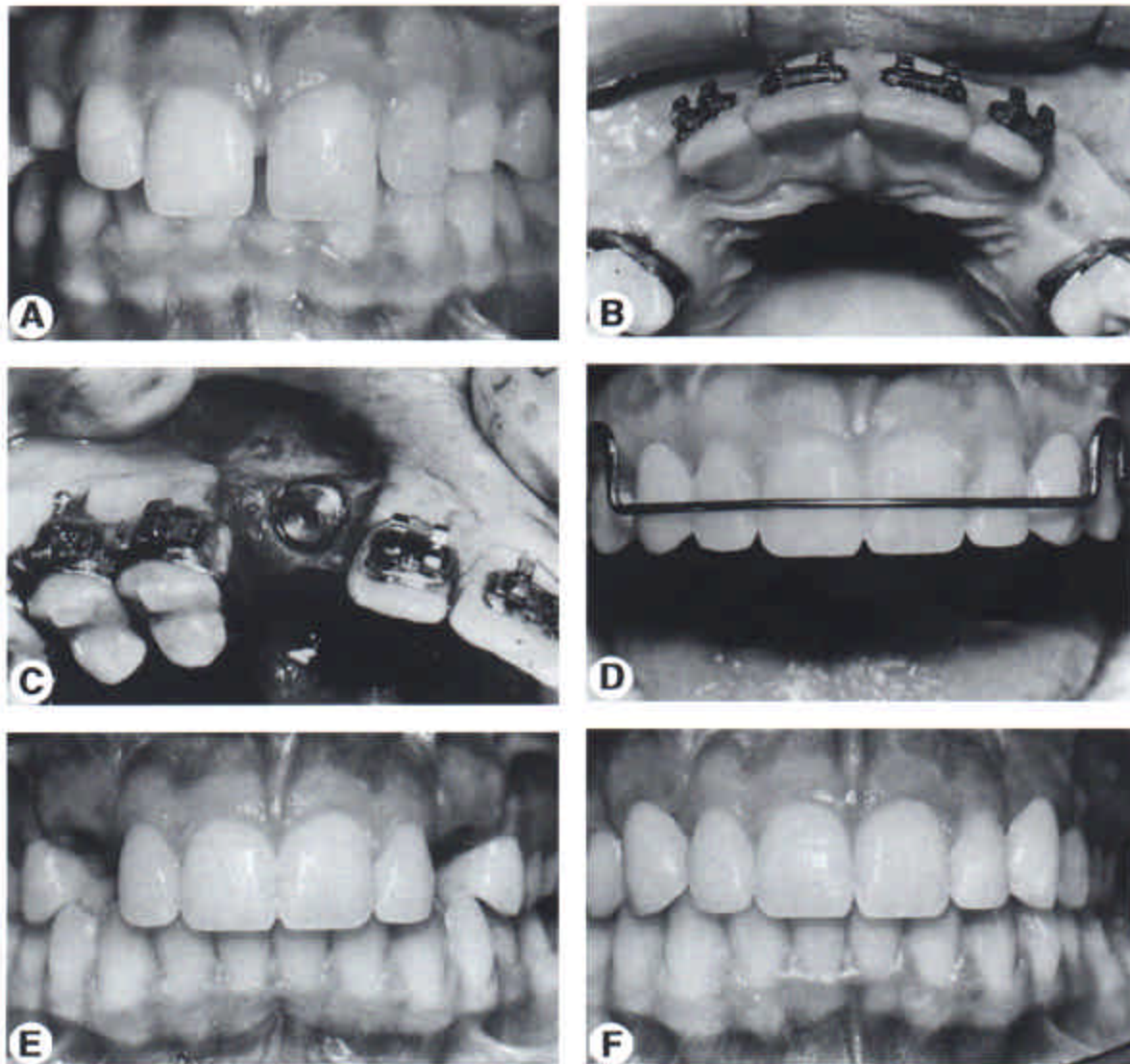
### Guided Eruption

If a primary second molar is ankylosed and submerged, and the second premolar is congenitally absent, it is important to extract the primary molar. This is especially true if the patient is young. By extracting the primary molar early, the first premolar will erupt into the space occupied by the primary molar (Fig 11). The first premo-

lar will bring bone as it erupts. As the teeth continue to erupt, the ridge will develop. At a later time, when orthodontic treatment is initiated, the first premolar and molar can be moved apart to create the edentulous ridge for placement of the implant (Fig 11).

### Orthodontic Movement

In some patients, extraction of an ankylosed primary second molar may have been delayed. The primary second molar becomes submerged as the adjacent teeth erupt. When the primary molar is eventually extracted, a significant verti-



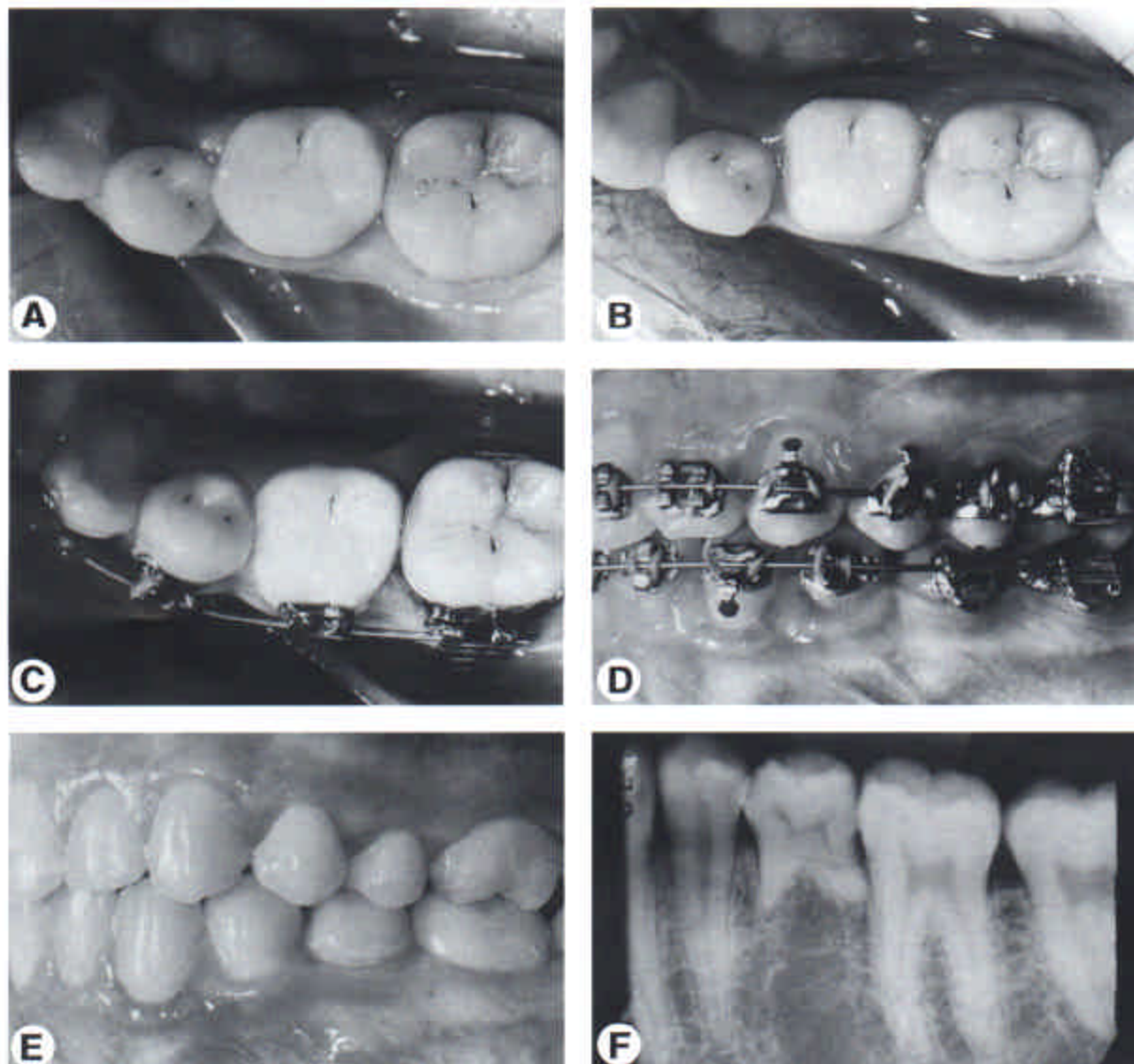
**Figure 9.** This patient was congenitally missing the maxillary right and left permanent canines (A). The primary canines were retained until the anterior teeth were aligned (B). Two months after extraction of the primary canines, the implants were placed (C). After orthodontic treatment (D) a maxillary retainer was placed to maintain the space before uncovering the implants (E). After uncovering, crowns were placed on both implants (F).

cal and buccolingual defect may be produced. Because of the reduced buccolingual thickness, an implant cannot be placed in this type of ridge. One option for correcting this problem is to place a bone graft in the area. The other option is to move the first premolar into the edentulous space and to place the implant in the position previously occupied by the first premolar.

A potential consequence of this type of tooth movement is that recession will occur as the premolar is moved into the edentulous space. However, previous studies have shown that alveolar cortical bone will be deposited ahead of the

tooth, if the tooth is moved slowly and if the gingival tissue is healthy. By moving the tooth slowly, the periosteum on the buccal and lingual surfaces of the alveolus will form bone as teeth are moved into the edentulous site. If the tooth is moved too rapidly, a dehiscence may occur.

In some patients, permanent teeth may have been extracted because of caries or trauma. The edentulous space may close and create a dental asymmetry (Fig 12). In these situations, instead of extracting three other permanent teeth to resolve the asymmetry, it may be more advisable to reopen the space and place an implant. When



**Figure 10.** This patient was congenitally missing the mandibular right second premolar and the primary second molar was not ankylosed (A and B). To create the appropriate amount of space for a second premolar implant, the primary molar was reduced in width (C and D). Two years after orthodontic treatment (E and F), the primary second molar is still in place, helping to maintain the alveolar width as well as space for an implant.

two teeth are moved apart orthodontically, alveolar bone will be deposited behind the teeth. This will recreate an edentulous ridge and allow an implant to be placed without bone grafting (Fig 12).

## Surgical Ridge Augmentation

### Ridge Resorption

Ridge resorption can occur in a buccolingual dimension and in an apicocoronal dimension. When the ridge is less than 4 mm in width,

augmentation procedures are required before placement of the implant (Fig 13C). Significant apicocoronal ridge resorption may have occurred and will also require augmentation. This can be accomplished before implant placement or at the time of implant placement, so that the head of the fixture will be positioned in the proper location for ideal restoration and esthetics. When the ridge width is in the 4 to 5 mm range, it may be possible to place the implant even though the buccal aspect may have a fenestration or dehiscence. The deficient area can be augmented at the time of placement?

(Fig 6). However, if the ridge is too narrow to stabilize the implant or place it in an appropriate functional and esthetic location, then pre-implant ridge augmentation will be necessary (Fig 13).

#### Timing of Ridge Augmentation

After the adjacent teeth are in proper alignment, ridge augmentation and/or implant placement can be accomplished. When grafting procedures are required to augment a ridge, it takes about 9 months for the bone graft to be stable enough to place an implant. In this situation, it is most advantageous to plan the procedure as soon as the proper tooth alignment is achieved by the orthodontist. This may mean that the procedure could be accomplished 1 year before band removal. This would allow the surgeon to proceed with placement of the implant near the end of orthodontic treatment or shortly after the appliances have been removed and a Hawley appliance, or other space maintaining device has been placed. After the graft has matured, an implant should be placed soon to avoid resorption of the grafted ridge (Fig 14E).

#### Ridge Augmentation Techniques

**Membranes.** Resorbable and nonresorbable membranes have been used to augment implant sites either before implant placement or at the time of implant placement if a dehiscence is present.<sup>8</sup> Augmentation can be accomplished in a buccal, lingual and incisal dimension. The nonresorbable membranes (Gore-Tex, W.L. Gore & Associates Inc, Flagstaff, AZ) tend to give better results because the barrier effect is more long-lasting. The resorbable membranes (Lambone [Ultimatics, Inc, Springdale, AR], collagen, Resolut [W.L. Gore & Associates]) will last only a few months, and after that period of time the barrier effect is diminished. This could have an adverse effect on the eventual amount of bone augmentation. The use of titanium reinforced Gore-Tex has improved the technique by allowing greater incisal (vertical) augmentation<sup>9</sup> (Fig 14). The reinforcement with titanium prevents collapse of the membrane which could also diminish the amount of bone growth.

The surgery involves a full thickness flap, decortication of the area to be grafted with a small round bur, and placement of graft material or a space making device<sup>10,11</sup> (Fig 13). Grafting

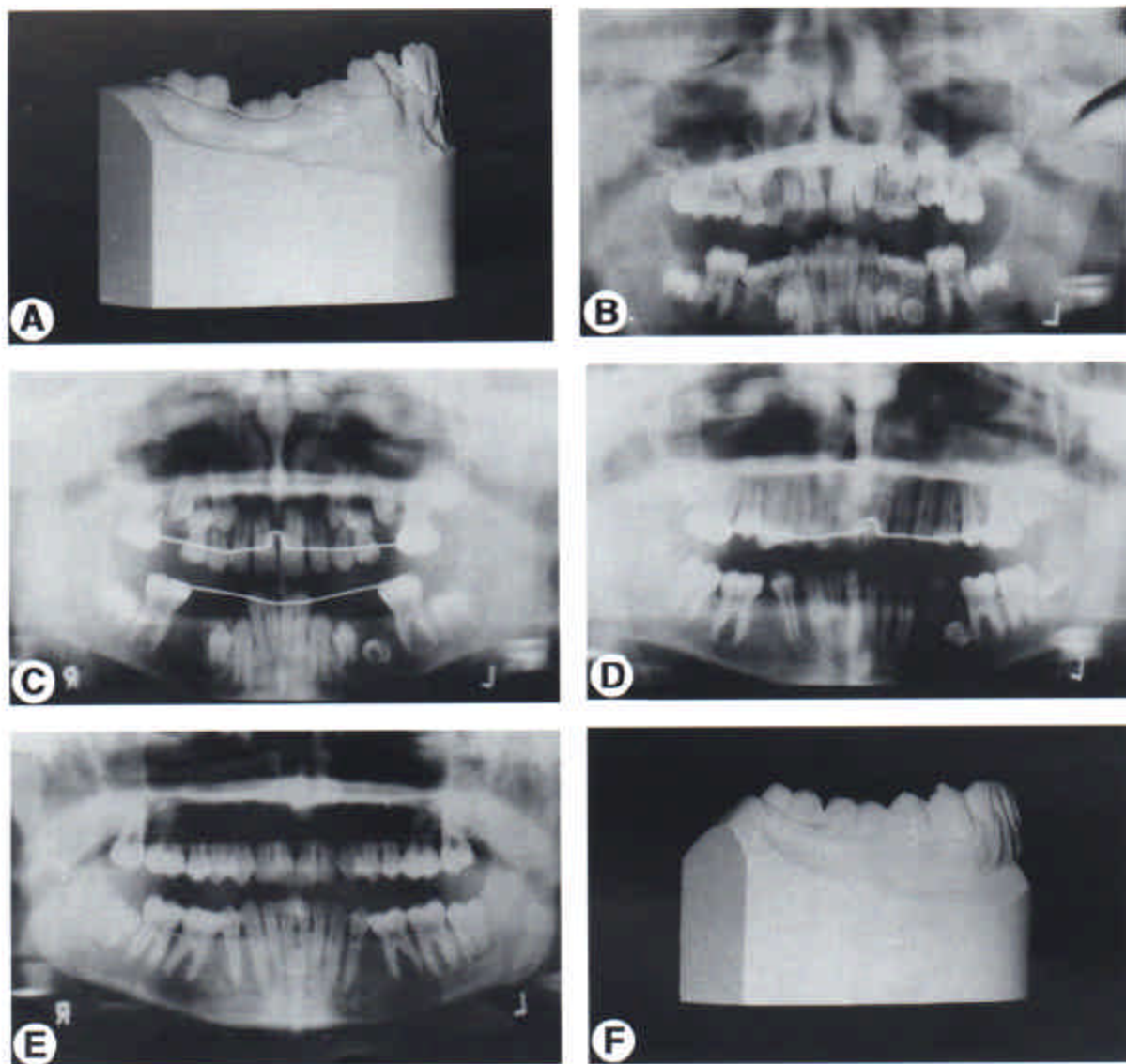
material is placed over the decorticated bone surface.<sup>12</sup> When a nonresorbable membrane (Gore-Tex) is used, it is preferable to stabilize the membrane at the periphery with screws or tacks (Memphix, Strauman, USA, Cambridge, MA) (Fig 14C). Membrane stabilization plays an important part in achieving maximum bone growth. The membrane seals this area from the flap which is returned to its original location and sutured.

Autogenous bone which can be obtained from the tuberosity, the ramus, or the symphysis area is the traditional choice. However, other types of materials such as freeze-dried bone and other allograft materials have been shown to accomplish adequate results (Fig 13). Allografts may require longer maturation time to achieve a solid bony base for placement of the implant. It is preferable to leave the nonresorbable membrane for at least 9 months or preferably longer to achieve optimum results. The disadvantage of a nonresorbable membrane is that it must be removed surgically. Resorbable membranes resorb in about 2 months. When the surgeon can place an implant and simply augment a small buccal dehiscence or fenestration, it is common to use a resorbable membrane. However, if a ridge needs to be augmented before implant placement, the nonresorbable membrane allows for a greater amount of bone growth on a more predictable basis.

**Bone grafts.** Another method of augmenting the ridge in a buccal, lingual, or incisal direction is to use blocks of bone.<sup>13</sup> These bone blocks can be obtained from the iliac crest, the mandibular symphysis, or from the mandibular ramus.<sup>14</sup> A full-thickness flap is reflected, the area is decorticated, and the block graft is shaped and screwed into the site. The flap is returned to its original location and sutured. These grafts have been very successful, especially for vertical augmentation. The disadvantage is the additional surgery, and expense. Bone blocks only require about a 6-month healing period before the implant can be placed. Occasionally, if the ridge is wide enough, the implant can be placed at the same time that the bone block is stabilized.<sup>15,16</sup> This is accomplished by drilling into the site and using existing bone and grafted bone to stabilize the fixture.

#### Osteotome Ridge Splitting Technique

The osteotome technique for ridge augmentation can be used if the ridge is 3 to 4 mm wide.<sup>17</sup>



**Figure 11.** This patient was congenitally missing the mandibular right second premolar. The mandibular left second premolar was malformed (A). The primary teeth were ankylosed and extracted (B). As the remaining teeth erupted (C, D, and E), the first premolar erupted distally in contact with the first molar (F).

Narrower ridges can also be widened with the addition of bone grafts. If the ridge is knife-edge, this technique will be problematic. The technique involves the use of sequentially larger osteotomes to expand the ridge so an implant can be placed. This is a slow wedging process to avoid splitting the ridge.

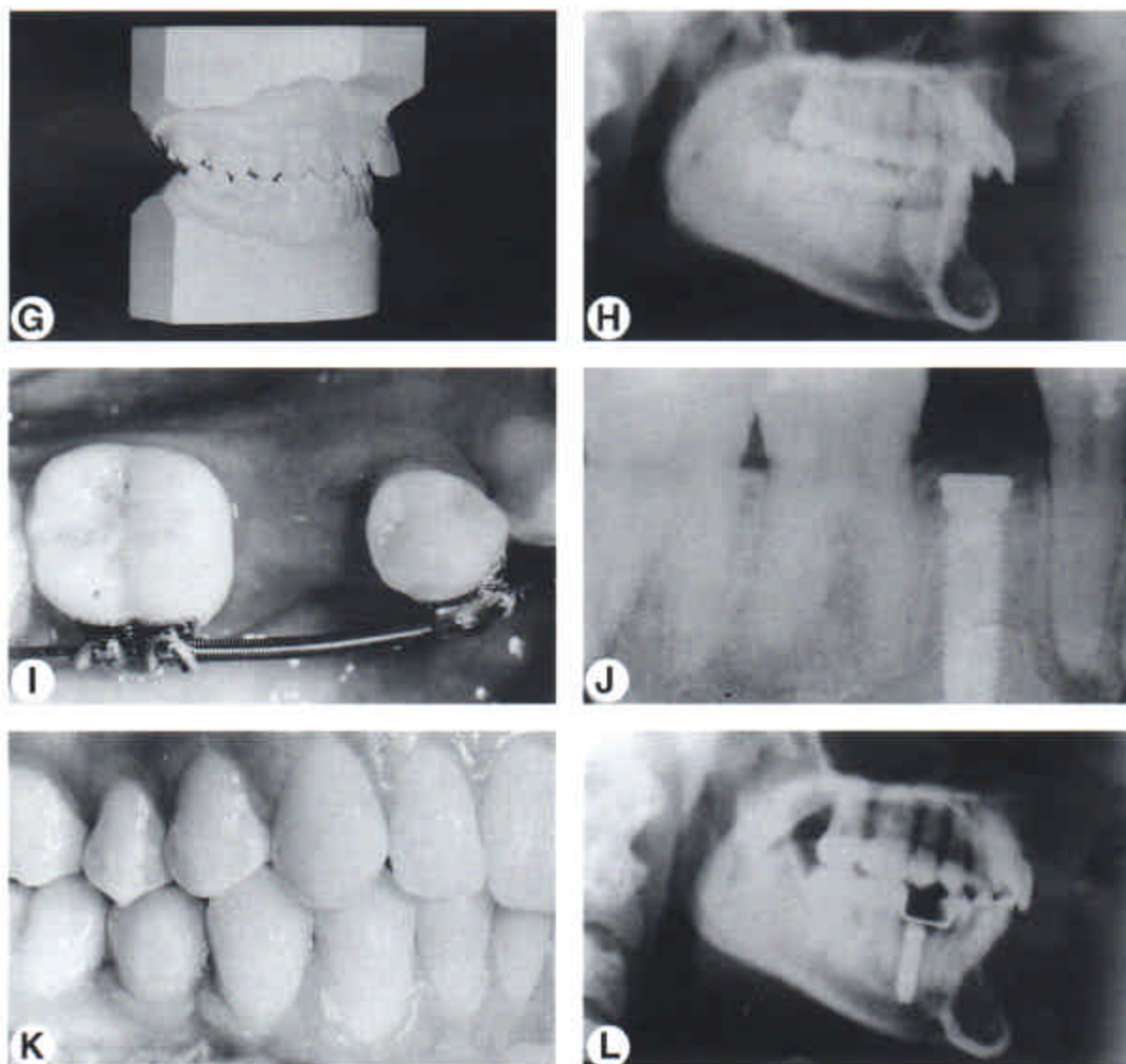
A similar technique involves actual ridge splitting. A full-thickness flap is reflected and a crosscut fissure bur is used to make a midcrestal cut. Small vertical cuts are made, and the ridge is split gently with an osteotome or chisel. A greenstick fracture is made, and the ridge is widened. Variations of this technique can involve either

placement of the fixture and/or placement of grafting materials within the split to maintain the widening of the ridge. The flap is returned to its original location and sutured. Approximately 6 months healing is required before either placement or uncovering of the implants.

## Space Maintenance

### During Orthodontics

If space has been created for an implant, it must be maintained during the orthodontic treatment. In the maxillary anterior region, plastic



**Figure 11.** (Cont'd). In order to reduce the overjet (G) and maintain upper lip support (H), space was opened for second premolar implants (I and J). After orthodontic treatment, the implants were restored with porcelain crowns (K and L).

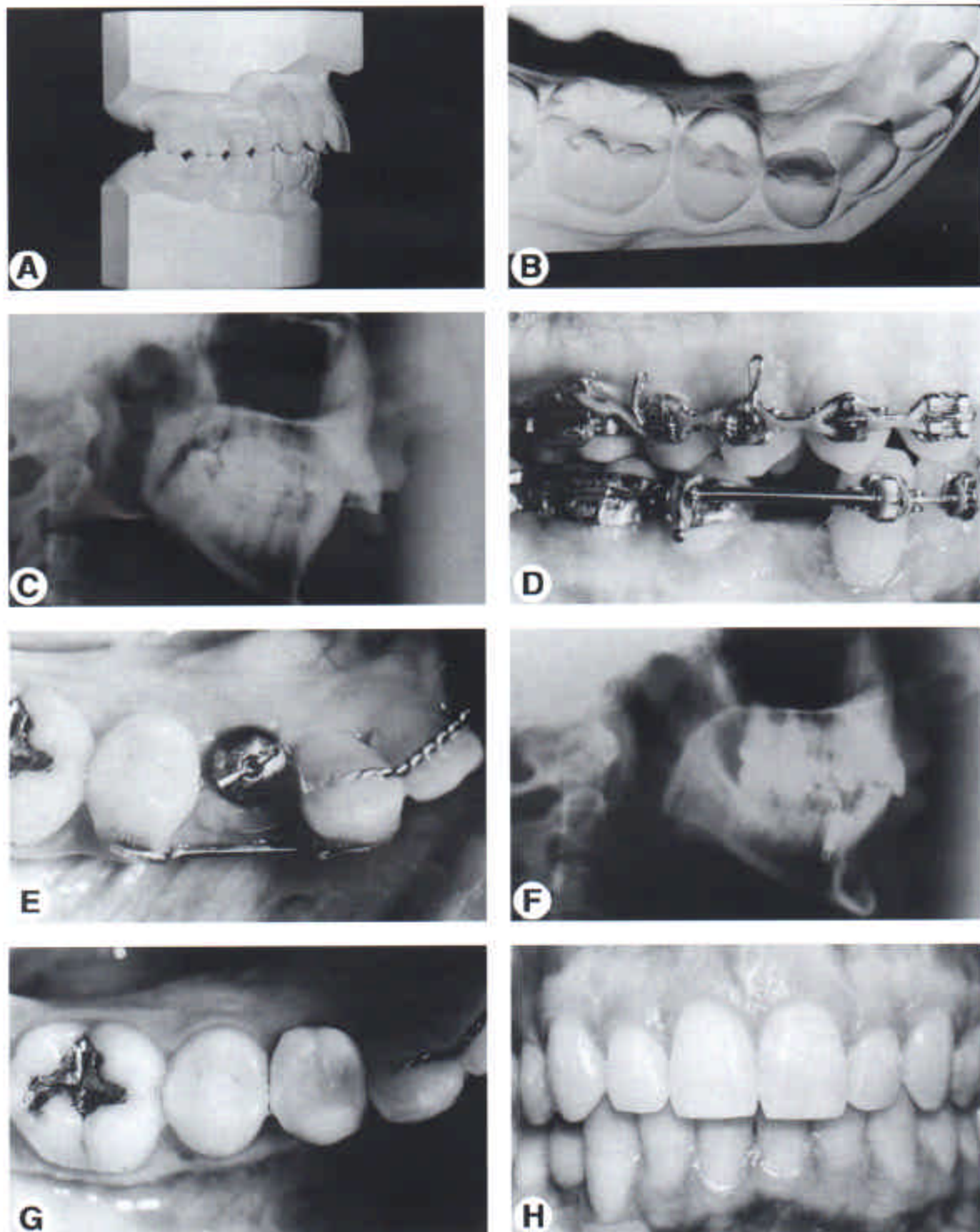
teeth can be shaped to fit into the edentulous space (Fig 15). Lateral incisor prosthetic teeth should be contoured to avoid impinging on the alveolar gingiva. It is important not to impinge on the tissue mesial and distal to the pontic, because this area will become the papilla after implant placement. A bracket can be placed on the tooth so that it can be attached to the archwire and ligated to the adjacent teeth. This will maintain the space during the completion of the orthodontic therapy.

In the mandibular posterior region, esthetics is not as critical. Therefore a prosthetic tooth is not necessary. In this situation, a piece of closed-

coil spring may be placed on the archwire to keep the first premolar and first molar apart during the finishing phase of orthodontics (Fig 3).

#### After Orthodontics

Maxillary lateral incisor implants usually are not placed until after orthodontics. If only a short period of time is anticipated between appliance removal and implant placement, a removable retainer with a prosthetic tooth is ideal (Fig 15). This will permit placement of the implant and uncovering of the implant while the retainer is being worn. It is important to adjust the retainer



**Figure 12.** This patient had the mandibular right first premolar extracted at an early age (A and B). As a result, the mandibular dental midline had shifted to the right and excess overjet had been created. To preserve facial esthetics (C), space was opened for a first premolar implant (D). After the implant was placed, it was uncovered, (E-H) and restored to improve the patient's occlusion and facial esthetics.



so that it rests on the cingula of the adjacent central incisor and canine. This will prevent impingement of the interproximal tissue and avoid inflammation and transmucosal loading of the implant. The plastic tooth on the retainer must be contoured to permit development of an adequate papilla around the implant (Fig 15D). The plastic tooth should be reinforced with wire to avoid breakage when the implant is uncovered, and the healing cap is placed. If a period of 4 or 5 years is anticipated before implant placement, it might be advisable to place a resin-bonded bridge as a temporary restoration to maintain the space. It is not reasonable to consider that the patient will wear a removable appliance over that period of time. A removable retainer with a prosthetic tooth will gradually deteriorate and become less esthetic over time.

After orthodontic treatment, mandibular posterior edentulous spaces should be maintained with a fixed rather than a removable retainer. It is difficult to construct adequate occlusal rests on the teeth to avoid impinging on the tissue with a removable retainer. In addition, younger patients may not wear the mandibular retainer and adjacent teeth could move. A fixed buccal retainer with a mesh pad that is bonded to the teeth is an excellent method of retaining this space (Fig 16). The wire should not interfere with the occlusion. It also must not interfere with the final impression for the implant crown. This type of retainer can be removed when the crown has been placed on the implant.

## Implant Placement

### Presurgical Planning and Stent Fabrication

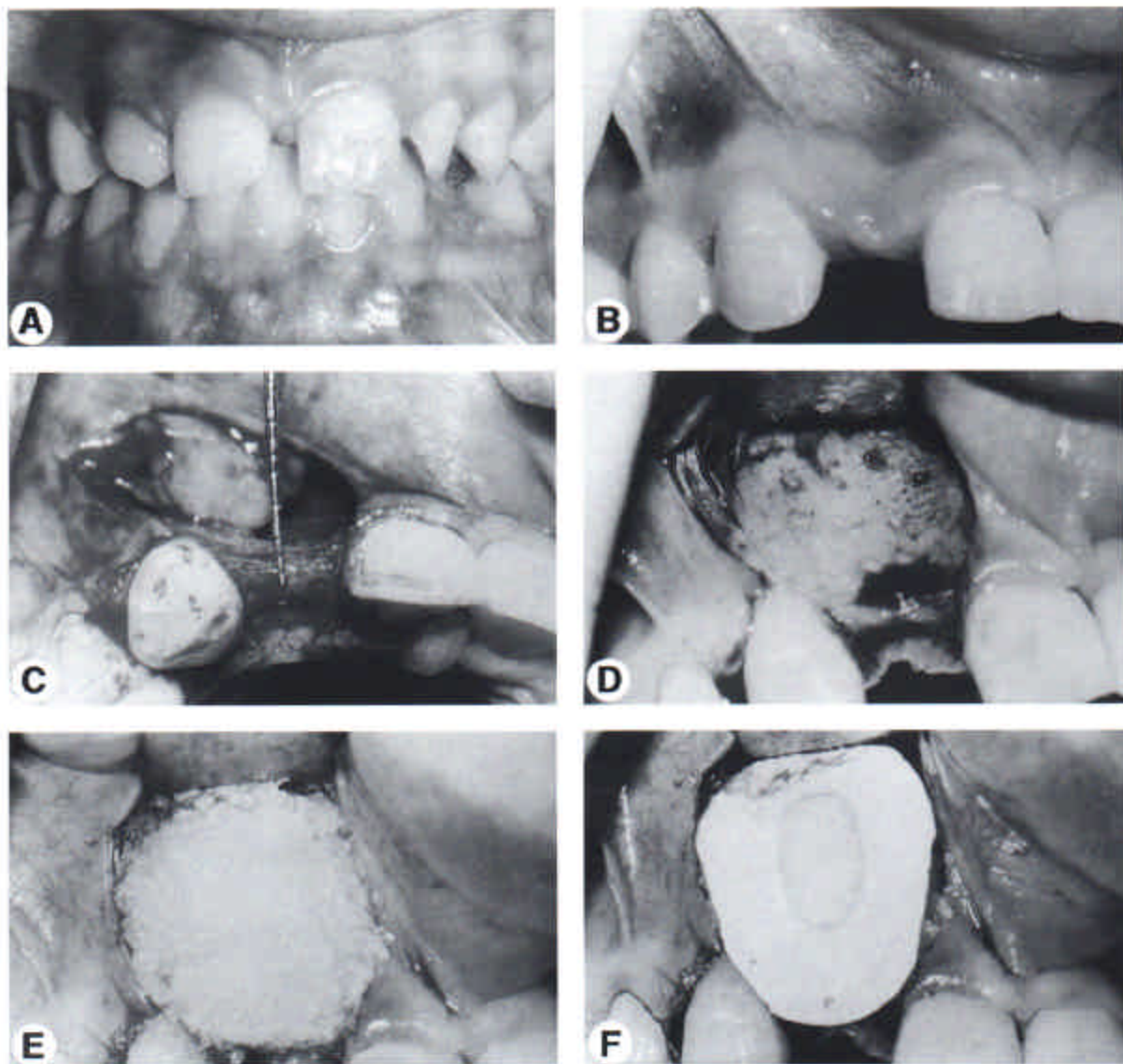
Presurgical planning requires a careful understanding of how implant placement affects the outcome of the final restoration. Three dimensions are considered when placing an implant: buccolingual position of the body of the fixture, buccolingual angulation, and depth of placement below tissue. To identify the correct location for placement in each of these areas, the ideal restoration must be envisioned. First, it should have a smooth labial emergence profile to provide support to the gingiva, and should be easy to clean. A ridge lap design should be avoided, because the esthetics are dependent on no change in the underlying soft tissue. The

angulation and depth should allow for minimal metal thickness below tissue so that no graying of the gingiva occurs. The depth should allow for a smooth contour, but not too far below tissue, so the technical aspects of impression making, temporization, and seating of the abutment and crown are facilitated.

By visualizing these ideal goals, the following guidelines can be used for presurgical planning and stent fabrication. The buccolingual position of the body of the implant should be as far to the labial as possible when esthetics is a concern. This provides the smoothest emergence profile from implant head to cervical contour of the restoration. The more lingual the implant is placed, the more abrupt this emergence profile will be. The angle of the implant should be directed at the incisal edge of anterior teeth or the central fossa of posterior teeth. For incisors, this angulation provides a smooth emergence profile, and the opportunity to create the thinnest possible metal collar on the abutment. The more facially the implant is angled, the thicker the metal collar must be to correct the angulation problem. The more palatal the implant is placed, the more abrupt the emergence profile becomes on the facial.

The depth of the implant should be 3 to 4 mm below the desired free gingival margin of the final restoration. This allows for 2 to 3 mm of porcelain below the tissue to provide the best color of the gingiva surrounding the implant. It also allows for minimal sulcular depth to avoid biological problems. It is the restorative dentist who is responsible for creating a stent that guides the surgeon so that these placement objectives can be met. The most critical areas that must be included in the stent to accomplish these goals are: the desired incisal edge position of the final restoration and the desired free gingival margin of the final restoration.

The simplest way to accomplish these objectives is to start with a diagnostic cast with the correct tooth position. Then a composite tooth with correct contour and gingival outline is created in the edentulous space using a light-cured material (Triad, Dentsply Trubyte, Trubyte Division, York, PA). After the tooth form is completed, the cast is lubricated and a clear pressure formed matrix is created from heavy stent material (Copyplast 1.0 × 125 mm, Great Lakes Ortho, Tonawanda, NY). Then this stent is trimmed to cover the incisal half of the ad-



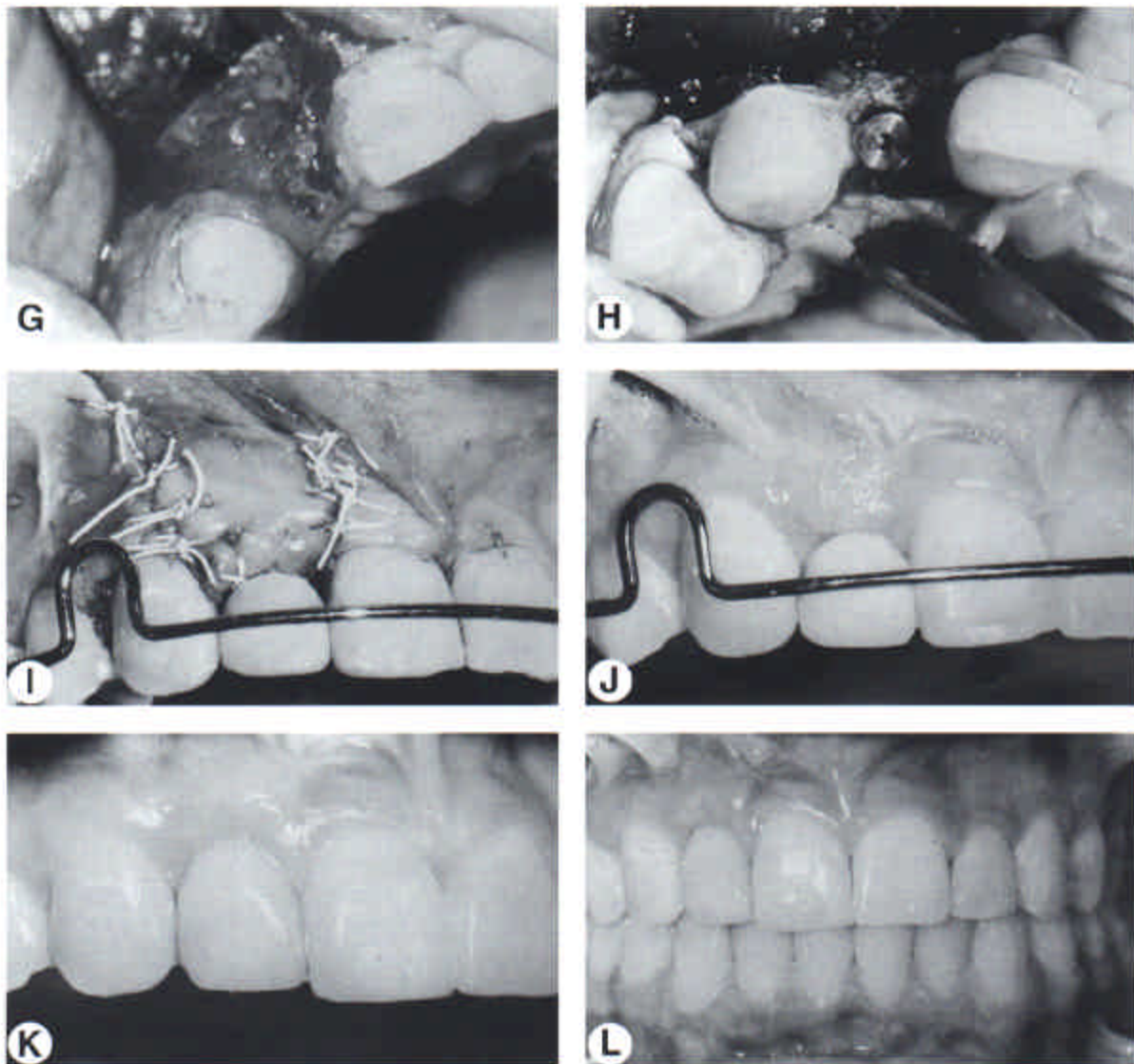
**Figure 13.** This patient was congenitally missing the maxillary right lateral incisor (A) and space was opened for an implant (B). Because the ridge was too narrow (C), a bone graft was placed (D and E) and covered with a membrane (F) to augment the ridge.

adjacent two teeth on each side of the edentulous area, and carefully adjusted to maintain the entire labial surface including the free gingival margin in the implant site (Fig 17). The incisal edge is then perforated in the center of the tooth mesiodistally with a number 8 round bur to allow the implant guide drill to fit through it (Fig 17). This simple stent provides all the key elements needed for implant placement, and can be used to index the fixture after it has been placed by simply cutting the incisal half of the tooth off in the implant area, and luting an impression

copied to the stent with quick-setting acrylic (GC-*Pattern Resin*, GC America Inc, Chicago, IL).

#### Implant Placement

The advent of multiple implant systems and sizes of fixtures has greatly facilitated the surgical process. When a patient is congenitally missing a maxillary lateral incisor, the space requirements are critical. Often, the mesiodistal width may be 5.0 to 6 mm. A standard size implant is 4 mm wide at the top platform. This leaves a narrow

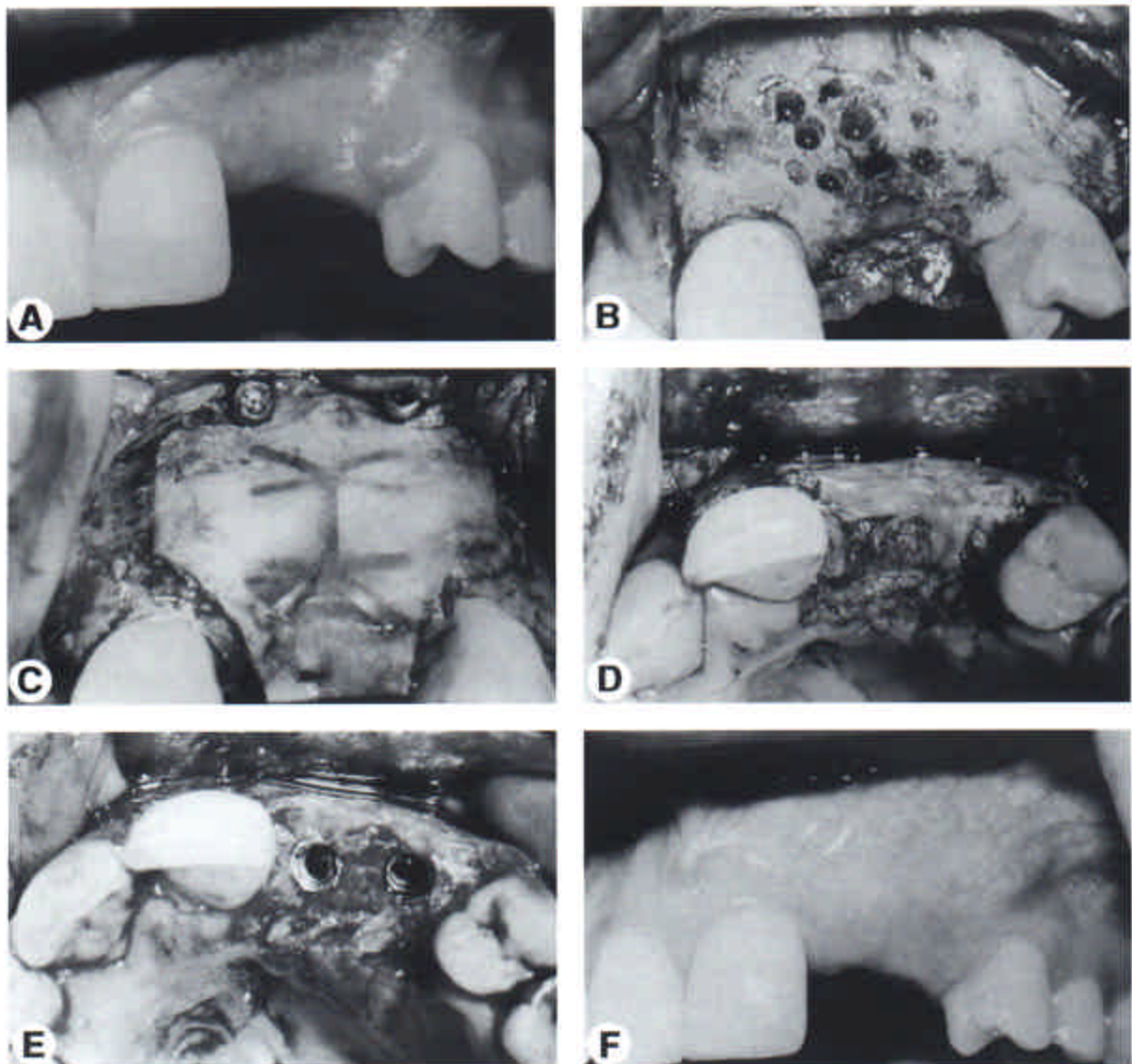


**Figure 13:** (Cont'd). After 8 months (G) an implant was placed (H) and the retainer was adjusted to permit healing of the tissue (I and J). After 6 months the final crown was cemented (K and L).

space between the head of the implant and the adjacent tooth, which makes restoration more difficult and creation of proper papillary form more challenging (Fig 1). With narrower implants (3.0 to 3.25 mm) it is possible to replace maxillary laterals and mandibular incisors and still leave more than 1 mm distance between the head of the implant and the adjacent tooth (Fig 2). Also, in ridges which are narrower buccolingually, the smaller implants are very useful in preventing dehiscences and fenestrations that would require additional grafting and possible use of membranes.

In the maxillary anterior region, bicortical stabilization can be achieved if the proper length of fixture is used. The apical end of the fixture can be stabilized in the cortical bone that borders the nasal spine, and the platform of the fixture can be stabilized in cortical bone on the crest of the ridge (Fig 5E).

The surgical technique is usually accomplished with a full thickness flap. If an implant is placed into an extraction site, minimal reflection of tissue is necessary buccally or lingually.<sup>18</sup> Sequentially larger twist drills are used to prepare the implant site. It is extremely important



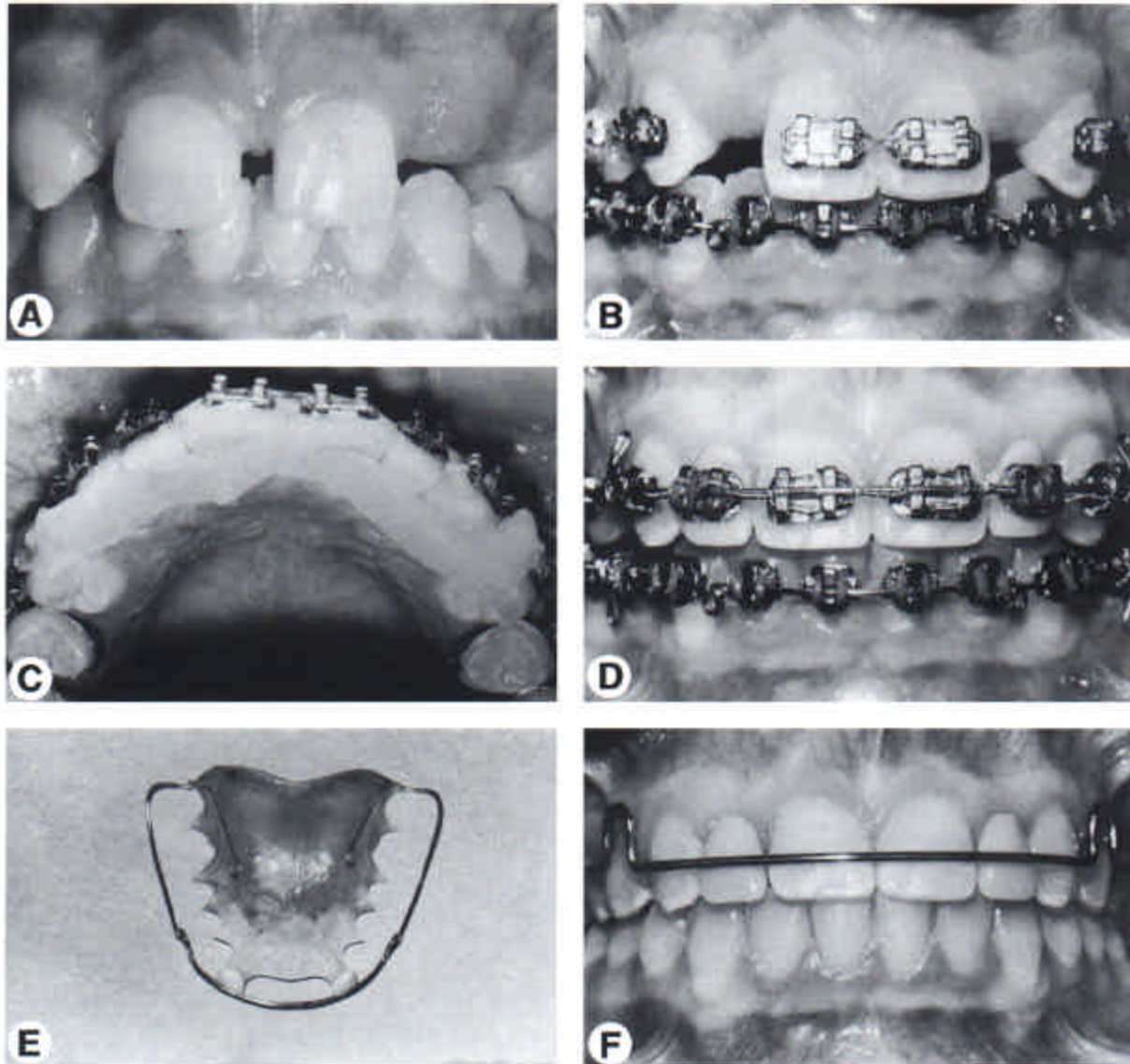
**Figure 14.** This patient had avulsed the lateral incisor and canine (A) and the ridge was decorticated. Reinforced membrane was used to prevent collapse of the soft tissue during bone augmentation (B, C, and D) so that implants could be placed with sufficient bone (E and F).

that adequate irrigation and cooling is maintained during drilling to minimize "burning of the bone" which can prevent integration and cause implant failure. A surgical stent is often used to help the surgeon place the fixture at an optimum angle, to facilitate the best functional and esthetic restoration (Fig 17).

Proper vertical placement of the implant is paramount in facilitating the restorative procedures. Some surgeons recommend placing the implant 3 to 4 mm apical to the adjacent cemento-enamel junction. However, this would place a maxillary lateral incisor implant too deep api-

cally and would create a sulcular depth of 6 mm or more from the gingival margin to the head of the implant. This may cause maintenance problems and potential gingival abscess. A better guideline for vertical placement of implants is to place the head of the fixture about 4 mm apical to the desired gingival margin. (Fig 17) This will produce an ideal emergence profile for the restorative dentist and also will create a maintainable 3 to 4 mm sulcular depth around the implant crown.

After placement of the implant, a cover screw is placed and the flaps are sutured to achieve



**Figure 15.** This patient is congenitally missing both maxillary lateral incisors (A). Space was opened for implants (B). To maintain the space during orthodontics, plastic teeth were contoured (C), bracketed (D), and placed on the arch wire. After orthodontic treatment (E) a maxillary retainer with two prosthetic teeth was placed to hold the space before implant placement (F).

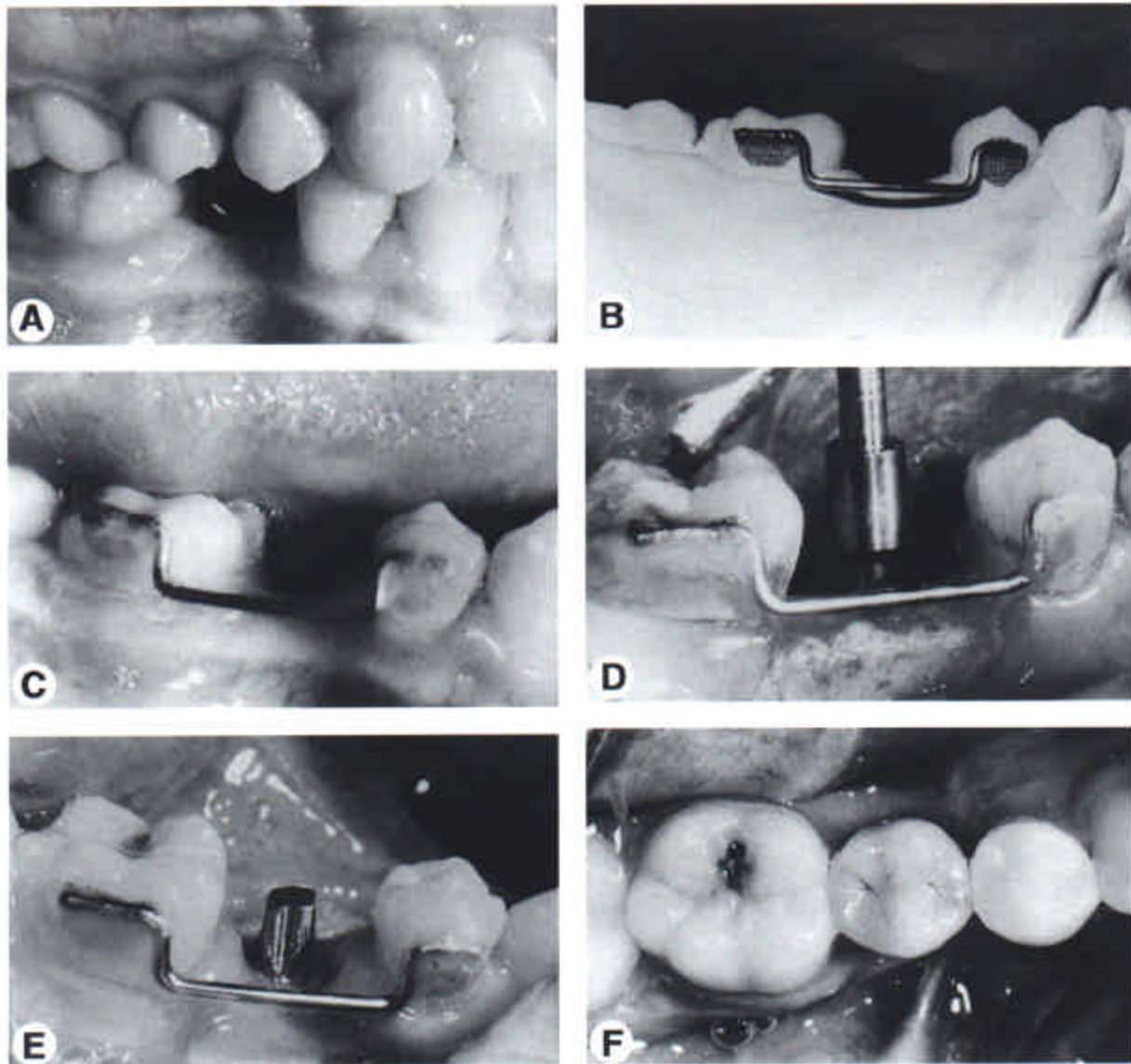
primary closure. Optimum healing time in the maxillary arch is 6 to 8 months. This will vary depending on the type of bone and whether or not bone grafting and membranes were placed. In the mandible 4 to 6 months is usually adequate to allow for osseointegration.

#### Temporary Restoration

For short-term temporization after implant placement, a removable retainer with an attached tooth is an acceptable option for most anterior teeth. However, a more precise bonded tempo-

rary restoration can be easily constructed. It is very stable, and is easy to remove and replace for any subsequent surgical procedures. The bonded temporary eliminates the risk of tissue impingement from a retainer. Patients often prefer a bonded temporary restoration. It is more esthetic and comfortable, and it will maintain interproximal tissue levels better than a removable retainer.

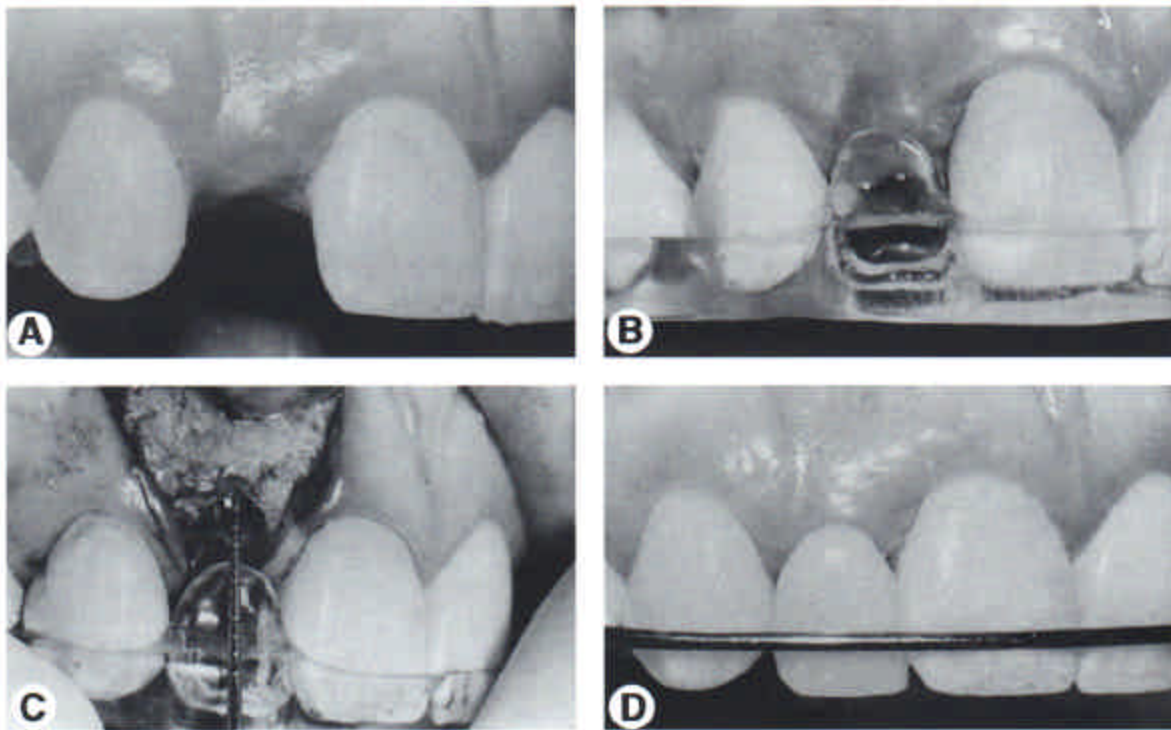
The construction is relatively simple. A study model is made of the edentulous area. A piece of 0.20 orthodontic wire is bent to lie 2 mm onto the lingual surface of the teeth adjacent to the



**Figure 16.** This patient was congenitally missing the mandibular right second premolar (A). After orthodontic treatment, a bonded wire and mesh retainer was placed to maintain the edentulous space (B and C). This is a very effective way of providing access for the surgeon and restorative dentist during implant placement and restoration (D, E, and F).

edentulous space without interfering with the occlusion. In addition, the bends extend the wire facially into the edentulous area so it is completely wrapped by the restorative material. Once the wire is bent, it can be held in place on the model with sticky wax, and then any tooth-colored composite can be modeled around the wire to the correct tooth color and form. The wire is chosen over the current reinforced mesh systems because it makes the temporary much easier to remove and replace.

The temporary is tried in the mouth, and then luted to the adjacent teeth with tooth-colored composite and acid-etch bonding. To remove it without damaging the adjacent teeth, a 7902 finishing bur is used to open up the facial embrasures. Then a high-speed brownie point (Shofu, Menlo Park, CA) is used to remove the composite around the wire. This point will take the composite off without abrading the tooth surface. After removal, the high-speed brownie is used to remove excess composite on the adjacent



**Figure 17.** After orthodontic treatment (A), a stent was constructed to duplicate the eventual gingival margin level of the final crown (B). This stent is used to establish the correct angular and vertical position of the implant (C and D).

teeth. At uncovering, this same temporary can be used by simply reshaping its undersurface to adapt to the healing abutment and tissue changes.

## Surgical Uncovering

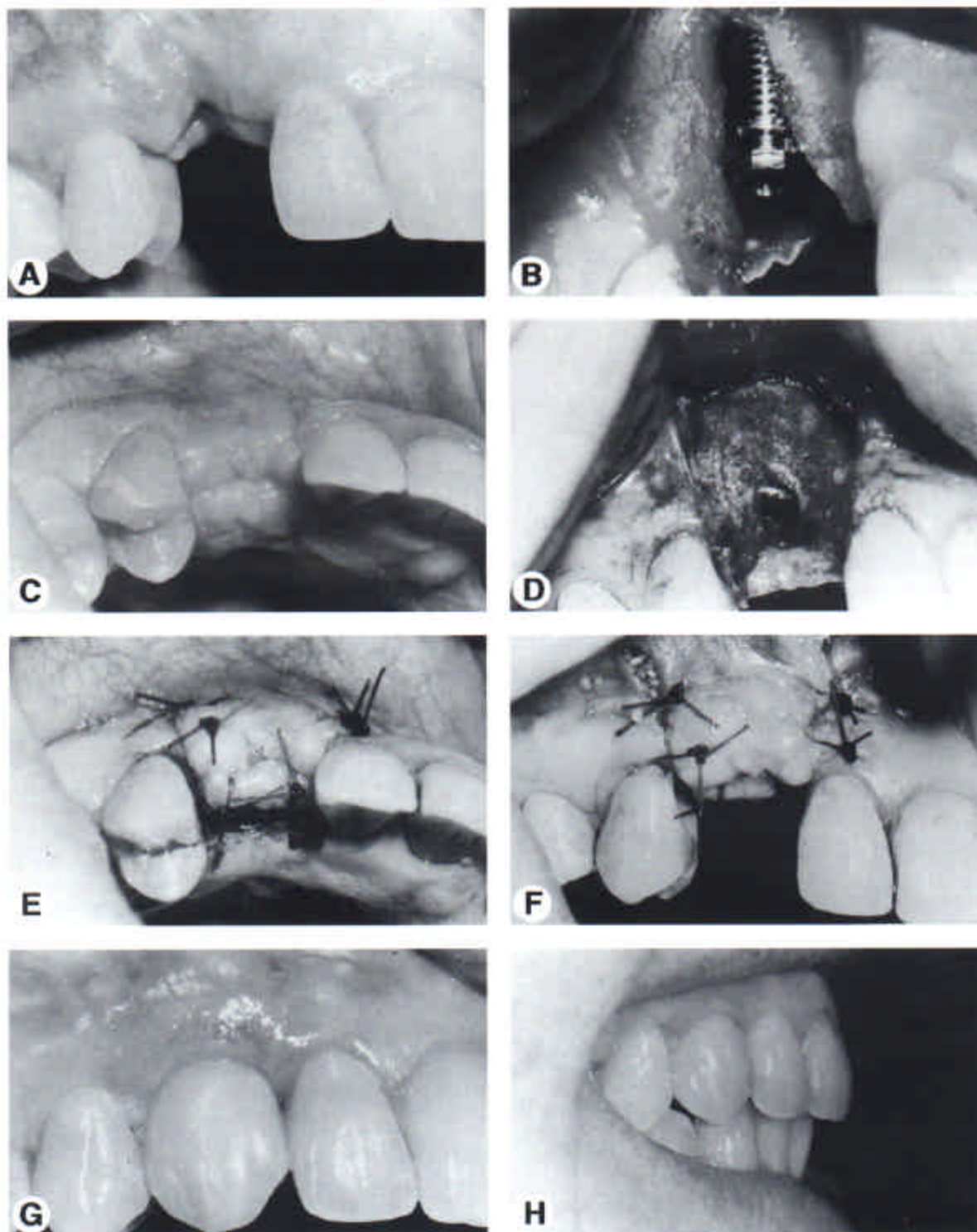
### Surgical Uncovering of the Implant

After the implant has had adequate time to osseointegrate, it can be uncovered. In the orthodontic patient, usually the bands and brackets have been removed, and the patient has either a removable or fixed retainer to maintain the edentulous space. Two different techniques can be used to uncover implants.

The most common technique is to reflect a full-thickness flap, place a temporary titanium healing abutment, and suture the flap around the abutment. In the maxillary arch, the full-thickness flap originates toward the palatal surface to gain as much attached gingiva as possible (Fig 18). Vertical incisions are made over the adjacent teeth and the full-thickness flap is reflected. Often, bone must be removed from the

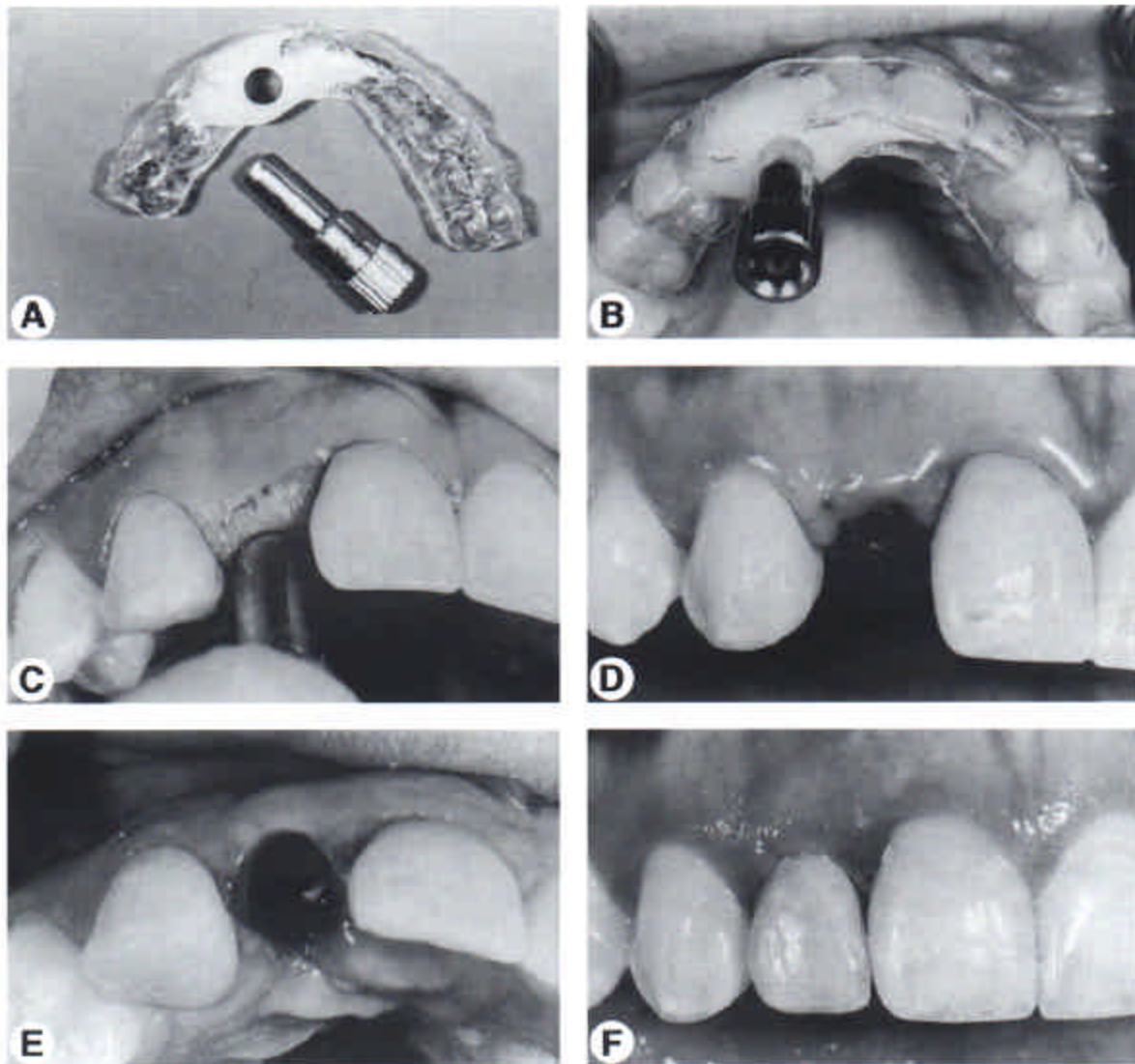
cover screw to allow for its removal. The proper size and length of the temporary healing abutment is selected and seated on top of the implant. Additional buccal augmentation can also be accomplished for improved esthetics. This can be done with either connective tissue taken from the palate or allograft materials. The flap is sutured slightly over the occlusal aspect of the healing abutment to permit maximum augmentation in a vertical direction (Fig 18). This will also permit reconstruction of the interproximal papillae. By using the palatal approach, the restorative dentist will have an optimum amount of thick attached gingiva which can be molded during the provisional stage. The flaps are sutured with resorbable sutures. In about 4 weeks the restorative dentist can begin the restorative process.

Another technique to uncover implants is the "punch technique" (Fig 19). This technique is not used often because it requires an ideal alveolar ridge. The ridge must have adequate thickness, adequate attached gingiva, ideal implant placement with proper angulation, and not



**Figure 18.** The maxillary right canine was traumatized, extracted (A), and an implant was placed 2 weeks after extraction (B). After 8 months (C), the implant was uncovered (D), and the tissue was positioned over the healing abutment (E and F). This facilitated contouring and regeneration of the marginal gingiva and papillae during restoration (G and H).





**Figure 19.** An uncovering stent (A) was created from an index of this lateral incisor implant during initial placement. A tissue punch (B) was used to precisely uncover the head of the implant (C) and avoid damaging the papillae (D and E). This also facilitated immediate placement of the temporary crown (F).

require any further buccal augmentation. If this technique is used, an additional procedure will be necessary when the implant is placed. At the time of surgery, the fixture can be "indexed." This index can be used by the restorative dentist to make a study model with an implant analogue that duplicates the intraoral implant location. From this model the restorative dentist can prefabricate a temporary restoration before the uncovering surgery (Fig 19). A guide-sleeve can also be made for precise placement of the surgical punch to uncover the top of the fixture. This surgical sleeve is made of an acrylic material

which fits over the teeth like a stent and allows for proper placement of the surgical punch. The punch is placed into the sleeve, moved down to the crest of the ridge, and then pressed into the tissue down to the head of the fixture (Fig 19). The plug of tissue is excised, and the cover screw is removed. An appropriate abutment can be placed and the temporary restoration is seated at the same time. This technique is atraumatic and with proper contouring and temporization, the patient can have an immediate provisional restoration at the time of the uncovering surgery. Again, this technique can only be used in the

ideal ridge. The advantages of this technique are reduced trauma, no temporary healing abutments, and the patient leaves the office with a contoured, esthetic, temporary restoration.

## Implant Restoration

### Implant Temporization

Temporization of the implant is an area which creates some confusion. The most common rationales given for the use of temporaries are the sequential loading of the implant to allow increased bone density before placing the final restoration, and soft tissue healing to a predictable level before the final impression. Since 6 to 8 months are allowed for implant healing before uncovering, sequential loading is not necessary for single anterior implants. The concerns over soft tissue healing are more critical.

### Soft Tissue Management After Implant Uncovering

The primary concern after the uncovering process is when to start the restorative phase of treatment. To achieve the best result in the finished restoration, the soft tissue should be healed to its ideal form around a temporary restoration. After healing is complete, a final impression can be made that captures the healed tissue so that the final restoration properly conforms to the gingiva.

For the restorative dentist, the major issue regarding temporization is timing. Should the implant be indexed at the time of placement and a temporary placed at uncovering, or should some tissue healing occur after uncovering, but before placing the temporary? Certain criteria should be assessed to answer these questions. If the edentulous ridge has inadequate facial bulk, inadequate interproximal tissue height, or inadequate vertical height in the free gingival margin area, the uncovering technique must also augment the inadequate areas. Whenever soft tissue augmentation is performed during the uncovering process, the temporary should not be placed at the same time. Instead, a healing abutment should be placed and the flap sutured partially over the abutment to tent the tissue above the bone (Fig 18E). A temporary restoration will not permit this type of uncovering technique. After 4 to 6 weeks of healing, an excess amount of tissue

is usually present, and a temporary can be placed to properly shape this soft tissue. The excess tissue should not be excised, because the temporary contour will help correct the tissue form.

To accomplish this, the patient is evaluated 4 to 6 weeks after uncovering and an impression made of the fixture. A study model is made and all the gingiva is removed from this model around the implant. A temporary is fabricated of light-cured composite on a temporary abutment. This temporary is contoured to the ideal shape of a tooth, ignoring the patient's current gingival form. If the augmentation was successful, there will be excess tissue around the implant and it will be difficult to seat the temporary restoration. Rather than modify the temporary or the tissue, the temporary is forced into position until it is seated completely. This may cause significant blanching of the tissue. Over the next 4 to 8 weeks, the tissue will remodel to fit the ideal crown form. After the tissue has reached the desired form, the temporary is removed and a final impression made of the fixture and the healed gingiva. The final restoration may then be completed.

If no soft tissue augmentation is necessary at uncovering, then a temporary can be placed on the same day that the implant is uncovered. To facilitate this, the implant can be indexed by the surgeon at time of placement using some form of stent (Fig 17C). The restorative dentist uses the index to produce a model with the implant analog properly oriented to the adjacent teeth. This model will serve two purposes. First, a temporary can be fabricated on the model before the uncovering process. Second, a surgical guide can be created that will enhance the uncovering process (Fig 19). Because no augmentation is necessary, the ideal uncovering only exposes the implant without any risk of damaging the soft tissue. This type of uncovering is best performed by a surgical punch approach (Fig 19). The difficulty is knowing where to aim the punch. This is where the analog model is used. The desired punch is seated over the head of the implant analog on the model. The punch is held so that its approach will be slightly from the palatal to avoid damaging the labial papilla. With the punch in the proper inclination a light-cured resin sleeve is created and extends around the circumference of the punch and onto the adjacent teeth (Fig 19). A clear pressure-formed

stent is then made of the composite sleeve to aid in seating the sleeve in the mouth. The excess is trimmed away leaving access for the punch to slide easily through the guide. Then, the punch and the guide stent are used to expose the implant without damaging the facial or interproximal tissue. After exposure of the implant, the preconstructed temporary is seated. Healing time before the final impression is now reduced to 4 to 8 weeks.

### Final Implant Restoration

The biggest decision facing the restorative dentist is whether the final crown on the single-tooth implant will be cemented or screw-retained. When multiple implants are being restored and splinted, the cemented approach offers several advantages. However, for single teeth, both cemented and screw-retained crowns can be used. The advantages of the screw-retained system are known retention and known retrievability. The disadvantage is the unesthetic access hole. The advantage of the cemented crown is esthetics because it has no access hole. The disadvantages of a cemented crown are unknown retention and unknown retrievability. The third option is to use a temporary cement (Temp Bond, Kerr Corp, Orange, CA), which works well for both retention and retrievability most of the time.

Actually, the decision between a cemented or screw-retained crown is usually dictated by the angle of the implant. A screw-retained restoration is only possible in the maxillary anterior when the screw access hole exits lingual to the incisal edge. If the implant access exits labial to the incisal edge a screw-retained crown will result in severe esthetic compromise.

In the posterior area, it is advantageous to use a screw-retained crown from a mechanical perspective. However, from esthetic and occlusal perspectives, the screw access opening is a problem. For these reasons, it is ideal to use cement-retained restorations in the posterior quadrants. The method of securing the crown also affects abutment design and placement. In a screw-retained restoration the primary concern is creating the correct subgingival contour. However, in a cemented restoration, it is also important to consider how far the cement margin will extend. The abutment should be shaped so that the cement margin is 2 to 3 mm below the free

gingival margin. If the margin is any deeper than this, the cement clean-up becomes very difficult. If it is any shallower, esthetics may be compromised.

It is also important to seat the abutment completely on the head of the fixture. It is effective to use an antibacterial paste (E-Z seat, Value Dental, Auburn, WA) on the end of the abutment at the time of seating. The implant abutment is dipped in a drop of paste and then seated. Complete seating is verified with a radiograph before final tightening with a torque driver. The use of this paste has been a great aid in rapidly achieving excellent tissue health around the final restoration.

### Long-Term Success Rate

Swedish researchers have been placing titanium implants in completely edentulous patients for more than 30 years. In these patients, five or six implants were placed in an edentulous maxilla or mandible. A denture was fixed to the top of the implants. These fixtures have been evaluated after 15 years of function. The long-term success rates for implants placed in this manner are very high.<sup>19</sup> Implants have also been used as abutments for fixed bridges. A 20 year follow-up of these types of restorations was performed by Swedish researchers. In their study, the continuous prosthesis stability rate was over 95%.<sup>20</sup>

Single-tooth implants have only been used for about the last 10 years. Long-term studies are not available. However, some follow-up studies have been published.<sup>21,22</sup> The five year success rate for single-tooth implants is well above 90%. Therefore, it seems that implant replacement of missing teeth is a viable and desirable option in the appropriate patient.

### Summary

This article has highlighted the various considerations that are necessary if implants are used as single-tooth replacements in orthodontic patients. Implants require interdisciplinary interaction. Orthodontists, surgeons, and restorative dentists must work together to produce an excellent result. Without interdisciplinary interaction, the final esthetic and functional result may be unacceptable. With a team approach, management of the single-tooth implant becomes more predictable and successful.

## References

1. Kokich V. Anterior dental esthetics: An orthodontic perspective III. Mediolateral relationships. *J Esthet Dent* 1993;5:206-207.
2. Odman J, Gröndahl K, Lekholm U, et al. The effect of osseointegrated implants on the dentoalveolar development. A clinical radiographic study in growing pigs. *Eur J Orthod* 1991;13:279-286.
3. Thilander B. Osseointegrated implants in adolescents. An alternative in replacing missing teeth. *Eur J Orthod* 1994;16:84-95.
4. Carlson G. Changes in contour of the maxillary alveolar process under immediate dentures. *Acta Odont Scand* 1967;25:1-31.
5. Kokich V. Single-tooth implants in young orthodontic patients. *Inform Orthod Kieferorthop* 1994;1:45-62.
6. Ostler MS, Kokich V. Alveolar ridge changes in patients congenitally missing mandibular second premolars. *J Prosthet Dent* 1994;71:144-149.
7. Nyman S, Lang NP, Buser D, et al. Bone regeneration adjacent to titanium dental implants using guided tissue regeneration: A report of two cases. *Int J Oral Maxillofac Implants* 1990;5:9-14.
8. Becker W, Becker B, Handlesman M, et al. Bone formation at dehiscenced dental implant sites treated with implant augmentation material: A pilot study in dogs. *Int J Periodont Rest Dent* 1990;10:93-101.
9. Jovanovic SA, Nevins M. Bone formation utilizing titanium-reinforced barrier membranes. *Int J Periodont Rest Dent* 1995;15:57-69.
10. Buser D, Dula K, Belser U, et al. Localized ridge augmentation using guided bone regeneration. I. Surgical procedure in the maxilla. *Int J Periodont Rest Dent* 1993;13:29-45.
11. Buser D, Dula K, Belser U, et al. Localized ridge augmentation using guided bone regeneration. II. Surgical procedure in the mandible. *Int J Periodont Rest Dent* 1995;15:11-29.
12. Nevins M, Mellonig JT. Enhancement of the damaged edentulous ridge to receive dental implants: A combination of allograft and the Gore-Tex membrane. *Int J Periodont Rest Dent* 1992;12:97-111.
13. Collins TA. Onlay bone grafting in combination with Brånemark implants. *Oral Maxillofac Surg Clin North Am* 1991;3:893-902.
14. Keller EE, Triplett WW. Iliac bone grafting: Review of 160 consecutive cases. *J Oral Maxillofac Surg* 1987;45:11-14.
15. Adell R, Lekholm U, Gröndahl K, et al. Reconstruction of severely resorbed edentulous maxillae using osseointegrated fixtures in immediate autogenous bone grafts. *Int J Oral Maxillofac Implants* 1990;5:233-246.
16. Keller EE, Tolman DE. Mandibular ridge augmentation with simultaneous iliac bone graft and endosseous implants: A preliminary report. *Int J Oral Maxillofac Implants* 1992;7:176-184.
17. Summers R. The osteome technique: Part 2. The ridge expansion osteotomy (REO) procedure. *Compend Contin Educ Dent* 1995;15:422-456.
18. Gelb DA. Immediate implant surgery: Three year retrospective evaluation of 50 consecutive cases. *Int J Oral Maxillofac Implants* 1993;8:388-399.
19. Adell R, Lekholm U, Rockler B, et al. A 15-year study of osseointegrated implants in the treatment of the edentulous jaw. *Int J Oral Surg* 1981;10:387-416.
20. Jemt T, Lekholm U, Adell R. Osseointegrated implants in the treatment of partially edentulous patients. A preliminary study of 876 consecutively installed fixtures. *J Oral Maxillofac Implants* 1989;4:211-217.
21. Jemt T, Lekholm U, Gröndahl K. A 3 year follow-up study of early single implant restorations ad modern Brånemark. *Int J Period Restor Dent* 1990;5:341-349.
22. Haas R, Mensdorff-Parielley N, Madath G, et al. Brånemark single-tooth implants: A preliminary report of 76 implants. *J Pros Dent* 1995;73:274-279.