

# The Esthetic Management of a Severe Isolated Periodontal Defect in the Maxillary Anterior

A 30-plus year-old woman presented to the periodontist with a chief complaint concerning the esthetics of the black space between her maxillary right lateral and central incisors (Figure 1). The history of the problem dated back several years when her general dentist noted increased pocket depth in this area. The patient was referred to a periodontist who elected to attempt grafting in this site to improve both the bone and soft tissue. The patient reported that after the initial surgery the defect became significantly worse and a large quantity of gingival tissue was lost. The patient was then referred to a second periodontist who, after evaluation, also chose to attempt both a bone and soft tissue grafting procedure and again the defect became worse. At that point the second periodontist referred the patient to the periodontist in our group for evaluation and treatment. At her initial consultation the patient indicated she had been managing the defect esthetically by placing pink wax into the large open space every day to minimize the appearance.

## Interdisciplinary Diagnosis and Treatment Planning

After evaluating the patient, the periodontist brought the patient's records to one of our network meetings for interdisciplinary diagnosis and treatment planning. Our initial goal was to determine the etiology of the defect. Both the right lateral and left central incisors tested vital in terms of their pulpal response, so we had to assume (because the remainder of her mouth was periodontally normal), that at some point in time there had been an isolated area of acute periodontitis between the maxillary right lateral and central incisors of unknown etiology. The real issue for our group became how to handle

the problem not only biologically, but also esthetically in order to meet the desires of this patient who had a very high lip line when she smiled.

## Rationale

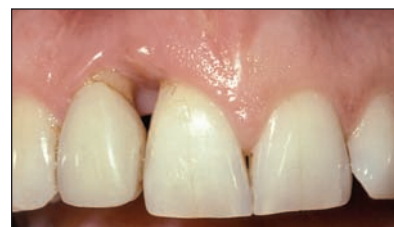To understand the rationale behind our treatment planning thought processes, it would be helpful to review the basic biology of the interproximal papilla area. The critical thought process that affects treatment planning is to understand how much gingival tissue can be maintained over the interproximal bone predictably. Several authors have evaluated this dimension, concluding that 4.5 mm is the average amount of gingival tissue that exists above the interproximal bone (Figure 2).<sup>1,2</sup> Therefore, when adjacent teeth are present the papillary height (assuming a normal gingival embrasure size) will always be somewhere in the 4-mm to 4.5-mm range above the interproximal bone.

This patient had approximately 5 mm of interproximal bone loss (Figure 3). Several treatment options were discussed at our interdisciplinary meeting. If the interproximal bone was the

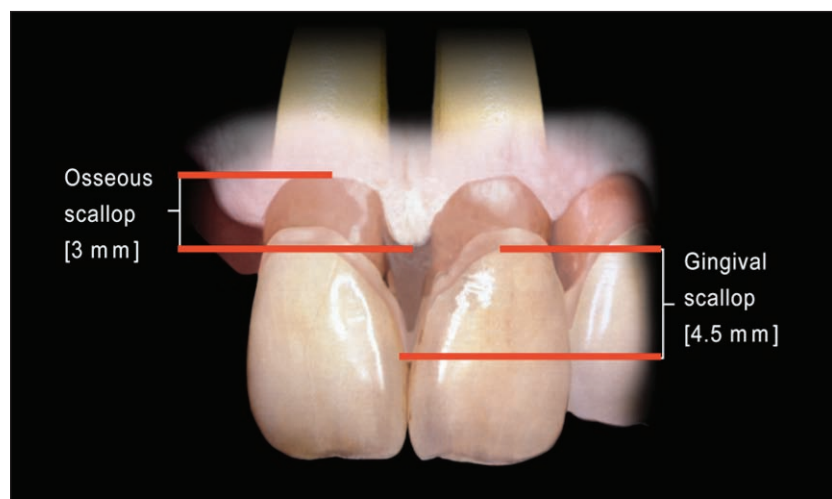
**Frank M. Spear, DDS, MSD**  
Founder and Director  
Seattle Institute for Advanced  
Dental Education  
Seattle, Washington

Affiliate Assistant Professor  
University of Washington  
School of Dentistry  
Seattle, Washington

Private Practice  
Seattle, Washington



**Figure 1**—The patient's chief complaint, a severe defect between the maxillary right lateral and central incisors.



**Figure 2**—Between adjacent natural teeth the body maintains 4.5 mm of gingival height above the interproximal crest of bone.

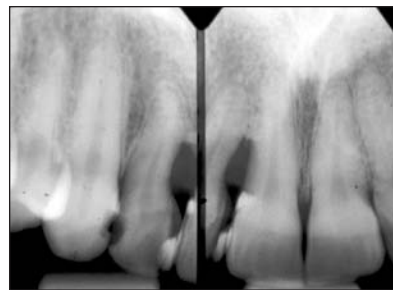problem, the obvious solution would be to graft 5 mm of bone, which, when combined with the 4.5 mm of tissue that would regenerate over the top of the bone, would solve this patient's dilemma. Unfortunately, even at this date in periodontics, growing bone vertically between adjacent teeth is virtually impossible unless you are attempting to fill a multiwall defect. Our periodontist believed that trying a third bone graft was not an option, which led to the idea of soft tissue grafting. Again, the challenge today is that there has not been a published report on any methodology to augment the interproximal papilla in such a way as to have it maintain itself long term. There have been isolated case reports showing that for a few months different surgical techniques have enhanced the height of the papilla. The challenge is that after gingival tissue is augmented interproximally, it violates the basic principles of how much soft tissue can be maintained above the interproximal bone; if the defect could actually be filled with soft tissue there would now be 9.5 mm of gingiva above the crest of bone. Given that the biologic attachment in this site is perhaps 2 mm, this would create a 7.5-mm periodontal pocket between the central and lateral incisors. The concept of attempting any soft tissue augmentation was, therefore, also ruled out as a treatment option. Our group then examined the idea of removing the lateral incisor.

To understand the thought process behind treatment planning with regard to tooth replacement it is necessary to understand the biology of the gingival tissues between teeth and implants and also between teeth and pontics. When there is a single tooth implant and an adjacent tooth, the height of the crest of bone on the adjacent tooth determines the height of the papilla. Similarly, there should be 4.5 mm of gingiva over the interproximal bone between an implant and an adjacent tooth (Figure 4).<sup>3-5</sup> When implants are placed adjacent to each other, the average amount of soft tissue that can be maintained above the interproximal crest of bone is 3 mm to 3.5 mm.<sup>6</sup> When a pontic is placed next to a tooth or an implant it has been found that after connective

tissue grafting, soft tissue can be maintained 6 mm to 9 mm above the crest of bone in the pontic region.<sup>7</sup> With this background information, it is now possible to examine all of the treatment options for the patient.

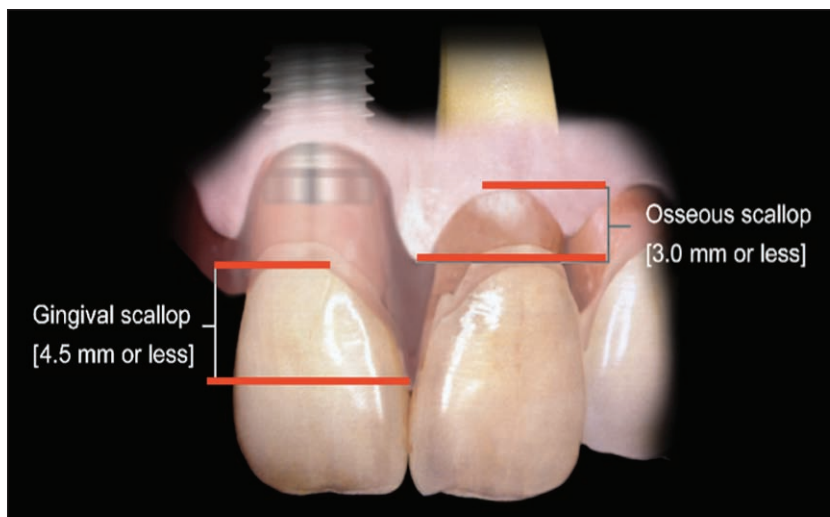
### Considering Treatment Options

The first tooth replacement consideration we evaluated was to remove the lateral incisor and replace it with a single tooth implant. Again, the critical number in that scenario was that the papilla would remain 4.5 mm above the crest of bone on the remaining natural teeth. Essentially, if the lateral incisor was replaced with an implant, the papilla would remain in exactly the same location that it was currently, 4.5 mm coronal to the remaining bone on the distal of the right central incisor. Because of this we ruled out the idea of removing the right lateral incisor and performing a single tooth implant. Our second treatment consideration was to remove both the right lateral and right central incisors and replace them with two adjacent implants. This option meant that 3 mm to 3.5 mm of gingiva above the bone was the best we could hope for between the adjacent implants. If we removed the right lateral and right central incisors and placed two adjacent implants without losing any of the interproximal bone that currently existed, 1 mm to 1.5 mm of papilla height would still be lost compared with the existing condition.

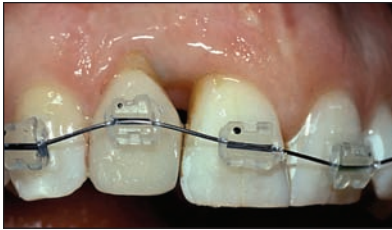


**Figure 3**—This radiograph shows that the fundamental problem is 5 mm of interproximal bone loss between the maxillary right lateral and central incisors.

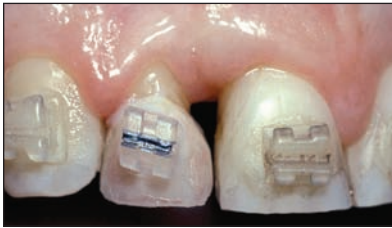
The next consideration was to remove the right lateral and right central incisors and bone graft the site vertically and then place adjacent implants. The soft tissue limitation between the two implants would still be 3 mm to 3.5 mm. However, if the bone graft was successful, the amount of bone that was augmented vertically could potentially raise the height of the papilla compared with its preexisting level. In realistically assessing how much vertical bone growth was achievable after the removal of the right lateral and right central incisors, our periodontist felt that, at best, perhaps 2 mm or at most 3 mm of vertical bone would be gained. If 3 mm of vertical bone was actually gained, followed by the additional 3.5 mm of soft tissue that would exist over the bone, it became evident that although the papilla would be improved, it would still be several millimeters short of matching the level of the adjacent natural teeth. Because of the unpredictability of the grafting, the



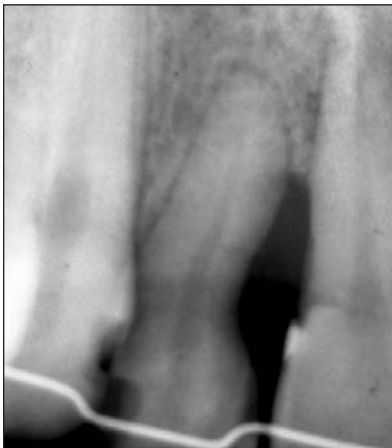**Figure 4**—When a single implant is placed adjacent to a natural tooth, the gingival height is maintained 4.5 mm above the interproximal bone on the remaining natural tooth.



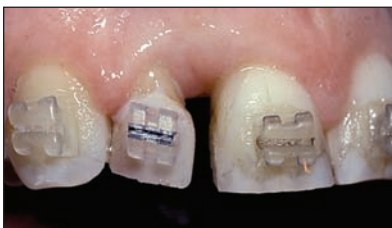**Figure 5**—The initial orthodontic bracketing design to erupt the maxillary right lateral and central incisors.



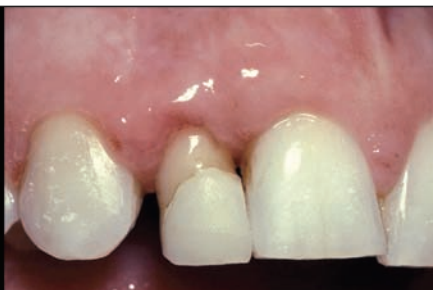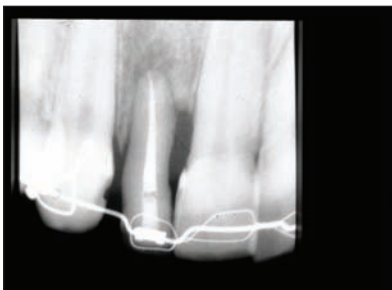
**Figure 6**—After the orthodontic extrusion, the gingival margin height on the lateral incisor is greatly improved but the interproximal embrasure is still quite large.



**Figure 7**—This radiograph shows a distal inclination in the root of the lateral incisor.



**Figure 8**—The width of the lateral incisor was narrowed on its mesial surface to allow the root to be brought closer to the central incisor.



**Figure 9**—A radiograph and clinical view of the root and gingival appearance at the completion of orthodontics.

concept of removing both teeth and performing the bone graft was also abandoned as a treatment option.

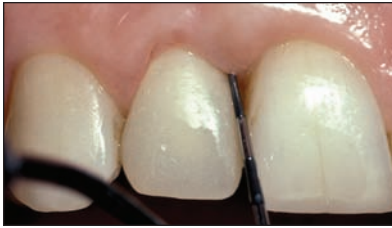Given the amount of soft tissue that can be maintained above the crest of bone when pontics are used, our next thought was to remove the right lateral incisor and convert it to a pontic by using a connective tissue graft to enhance the tissue height. The connective tissue graft would then be able to maintain significantly more gingiva above the bone than any of the other techniques that use implants. The challenge, however, was that if the connective tissue graft was successful and maintained 6 mm to 9 mm of tissue above bone, the distal of the right central incisor would be left with a 7-mm to 8-mm periodontal pocket. This technique, however, had the most predictable outcome in terms of improving the height of the papilla because connective tissue ridge augmentation is a highly predictable procedure. Ultimately, after evaluating all of the previously mentioned options, our group determined that the ideal solution to this problem was to in fact move the bone. The bone was obviously creating the treatment challenges and if we could correct the bone level, we could minimize the difficulty of treatment.

Moving the bone is known as orthodontic eruption. It is important to note that orthodontically erupting only the right lateral incisor was not going to resolve the interproximal problem. Erupting the right lateral incisor would move the facial tissue and bone on that tooth coronally, but after its removal the bone level on the right central would still dictate the interproximal tissue level. Therefore, if the interproximal bone was to be moved coronally between the right lateral and central incisors, it

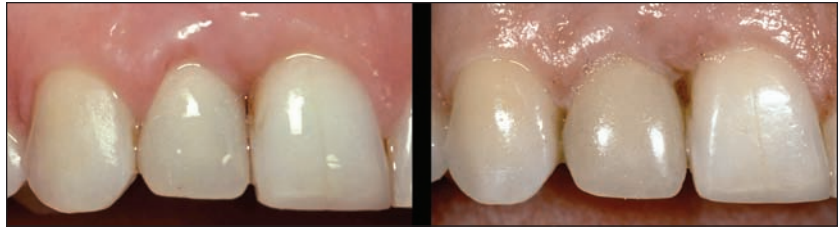would be necessary to erupt both teeth coronally.<sup>8</sup> As the teeth moved in a coronal direction, they would bring the facial tissue and bone with them as well as the interproximal bone. We decided to erupt the teeth as much as possible.

This patient's treatment began with a thorough debridement of the area, followed by the placement of orthodontic brackets so that both the right lateral and right central incisors would erupt. The intention was to have the right lateral incisor erupt the most (Figure 5). The initial goal was to bring the right lateral incisor coronal until the facial gingival margin was at the correct level when compared with the maxillary left lateral incisor. Meanwhile, attention was being paid to the interproximal tissue and bone as the teeth were brought down. It is helpful if the eruptive process is slow for the bone and tissue to follow. Our orthodontist generally proceeds at 0.5 mm to 1 mm per month of eruption and then maintains this position 1 month for each millimeter of coronal movement. As the teeth were brought down, the gingival tissues responded better than expected, with the facial gingiva on the right lateral incisor coming down to almost an ideal level when compared with the maxillary left lateral incisor (Figure 6). At this point in treatment, however, the interproximal embrasure was still quite large. A radiograph revealed that the root of the lateral incisor was inclined to the distal, leaving a very large gingival embrasure (Figure 7). It was decided that the width of the lateral incisor crown needed to be reduced on its mesial surface to allow the root to be positioned mesially and to minimize the size of the gingival embrasure (Figure 8). The lateral incisor had become quite sensitive, so we decided to remove the pulp and complete endodontic therapy. The next phase of orthodontic therapy was to move the root and crown of the lateral incisor against the distal of the central incisor. As this movement occurred, the gingival embrasure decreased in size, the contact moved apically, and the papilla moved coronally (Figure 9). This completed the orthodontic phase of treatment.

It was now time to reevaluate treatment options. The papilla was not



**Figure 10**—At the completion of orthodontics and placing of a temporary crown the lateral incisor probed only 4 mm.

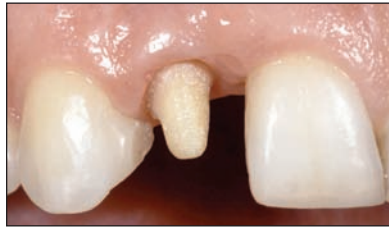

**Figure 11**—On the left is the completion of orthodontics and placement of the temporary crown. The right shows the results 1 year later. Note the slight amount of recession that has occurred.

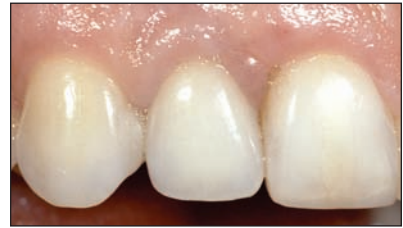ideal, and radiographically the tooth still looked questionable, but our team agreed that any of the alternatives involving tooth removal would likely not have reached the result we had achieved by maintaining the lateral incisor. At this point we decided to temporize the maxillary right lateral incisor by splinting it on the lingual, with a wire, to the right canine to provide some support until the lateral was less mobile. Probing the mesial of the right lateral indicated a sulcus depth of 4 mm (Figure 10). The temporary was left in place for 1 full year, during which time there was some recession of the interproximal papilla between the right lateral and central (Figure 11). However, the lateral incisor was not mobile and did not bleed on probing, the depth of which was still less than 4 mm (Figure 12). A final metal ceramic crown was completed and a pink porcelain papilla was made to make up for the small amount of soft tissue that was still missing (Figure 13). Initially a wire was used on the lingual of the metal ceramic crown, splinted to the right canine. This wire remained in place for almost 6 years; it has not been replaced for the past 4 years (Figure 14). Both the mobility and probing have remained unchanged during the 10 years since treatment. There has been virtually no change in the soft tissue level surrounding this tooth (Figures 15 and 16).

## Conclusion

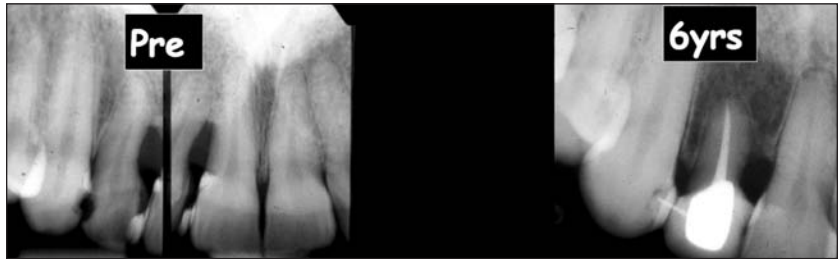
The purpose of this article has been to describe how one patient who presented with a severe isolated periodontal defect in the anterior was treated. It is our hope that the readers will be aware of the benefits of interdisciplinary treatment planning in a patient such as this. Despite the progress in regenerative procedures and implants, patients such as this would be very difficult to



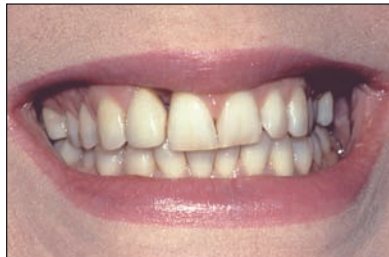**Figure 12**—At the time of the final crown placement, the tissue is healthy and probes less than 4 mm.



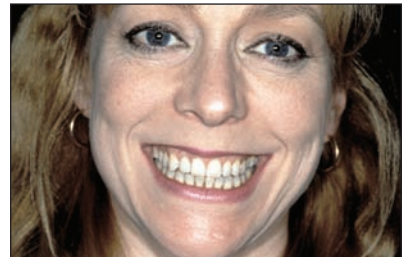**Figure 13**—A small porcelain papilla was added to the final crown as a prosthetic to replace the small amount of missing papilla.



**Figure 14**—Radiographs preoperatively and 6 years posttreatment illustrate the periodontal health of the bone surrounding both the lateral and central incisors.



**Figure 15**—The patient's pretreatment smile without the pink wax in place.



**Figure 16**—The patient's smile at 6 years posttreatment.

treat if the lateral incisor had been removed at the beginning of treatment.

## References

1. Tarnow DP, Magner AW, Fletcher P. The effect of the distance from the contact point to the crest of bone on the presence or absence of the interproximal dental papilla. *J Periodontol.* 1992;63:995-996.
2. van der Velden U. Regeneration of the interdental soft tissue following denudation procedures. *J Clin Periodont.* 1982;9(6):455-459.
3. Choquet V, Hermans M, Adriaenssens P, et al. Clinical and radiographic evidence of the papilla level adjacent to single-tooth dental implants. A retrospective study in the maxillary anterior region. *J Periodontol.* 2001; 72(10):1364-1371.
4. Grunder U. Stability of the mucosal topography around single-tooth implants and

adjacent teeth: 1-year results. *Int J Periodontics Restorative Dent.* 2000;20(1):11-17.

5. Kan JY, Rungcharassaeng K, Umezue K, Kois JC. Dimensions of peri-implant mucosa: An evaluation of maxillary anterior single implants in humans. *J Periodontol.* 2003; 74(4):557-562.
6. Tarnow DP, Cho SC, Wallace SS. The effect of interimplant distance on the height of interimplant bone crest. *J Periodontol.* 2000; 71(4):546-549.
7. Salama H, Salama MA, Garber D, Adar P. The interproximal height of bone: A guidepost to predictable aesthetic strategies and soft tissue contours in anterior tooth replacement. *Pract Periodontics Aesthet Dent.* 1998; 10(9):1131-1141.
8. Salama H, Salama M, Kelly J. The orthodontic-periodontal connection in implant site development. *Pract Periodontics Aesthet Dent.* 1996;8(9):923-932.