

Interdisciplinary Management of Anterior Dental Esthetics

Spear FM, Kokich VG, Mathews DP. Interdisciplinary management of anterior dental esthetics. *JADA* 2006;137(2):160-9.
Copyright © 2006 American Dental Association. All rights reserved. Reprinted with permission.



Frank M. Spear, DDS, MSD
Founder and Director
Seattle Institute for Advanced
Dental Education
Seattle, Washington
Affiliate Assistant Professor
University of Washington
School of Dentistry
Seattle, Washington
Private Practice
Seattle, Washington

Vincent G. Kokich, DDS, MSD
Professor
Department of Orthodontics
School of Dentistry
University of Washington
Seattle, Washington

David P. Mathews, DDS
Affiliate Assistant Professor
Department of Periodontics
School of Dentistry
University of Washington
Seattle, Washington

Abstract:

Background. Dental esthetics has become a popular topic among all disciplines in dentistry. When a makeover is planned for the esthetic appearance of a patient's teeth, the clinician must have a logical diagnostic approach that results in the appropriate treatment plan. With some patients, the restorative dentist cannot accomplish the correction alone but may require the assistance of other dental disciplines.

Approach. This article describes an interdisciplinary approach to the diagnosis and management of anterior dental esthetics. The authors practice different disciplines in dentistry: restorative care, orthodontics and periodontics. However, for more than 20 years, this team has participated in an interdisciplinary dental study group that focuses on a wide variety of dental problems. One such area has been the analysis of anterior dental esthetic problems requiring interdisciplinary correction. This article will describe a unique approach to interdisciplinary dental diagnosis, beginning with esthetics but encompassing structure, function and biology to achieve an optimal result.

Clinical Implications. If a clinician uses an esthetically based approach to the diagnosis of anterior dental problems, then the outcome of the esthetic treatment plan will be enhanced without sacrificing the structural, functional and biological aspects of the patient's dentition.

Key Words. Interdisciplinary dentistry; anterior dental esthetics; crown length; anterior tooth wear; gingival levels; crown lengthening; orthodontic intrusion; width-to-length ratio; resting lip level; diagnostic wax-up.

Learning Objectives

After reading this article, the reader should be able to:

- explain the treatment planning sequencing concept of beginning with esthetics and working toward biology.
- describe the steps to integrating function and esthetics when assessment of esthetics is accomplished first in the treatment planning process.
- discuss how the decisions made in each individual assessment category impact the eventual outcome of the case.

In the past 25 years, the focus in dentistry has changed gradually. Years ago, dentists were in the repair business. Routine dental treatment involved excavating dental caries and filling the enamel and dentinal defects with amalgam. In larger holes, more durable restorations may have been necessary, but the focus was the same: repair the effects of dental caries. However, with the advent of fluorides and sealants, as well as a better understanding of the role of bacteria in causing both caries and periodontal disease, the needs of the dental patient have changed gradually. Many young adults who are products of the sealant generation have little or no caries and few existing restorations. At the same time, our image of

the value of teeth in Western society also has changed. Yes, the public still regards teeth as an important part of chewing, but today the focus of many adults has shifted toward esthetics ("How can my teeth be made to look better?"). Therefore, the formerly independent disciplines of orthodontics, periodontics, restorative dentistry and maxillofacial surgery often must join forces to satisfy the public's desire to look better.

This trend toward a heightened awareness of esthetics has challenged dentistry to look at dental esthetics in a more organized and systematic manner, so that the health of the patient and his or her teeth still is the most important underlying objective. But some existing

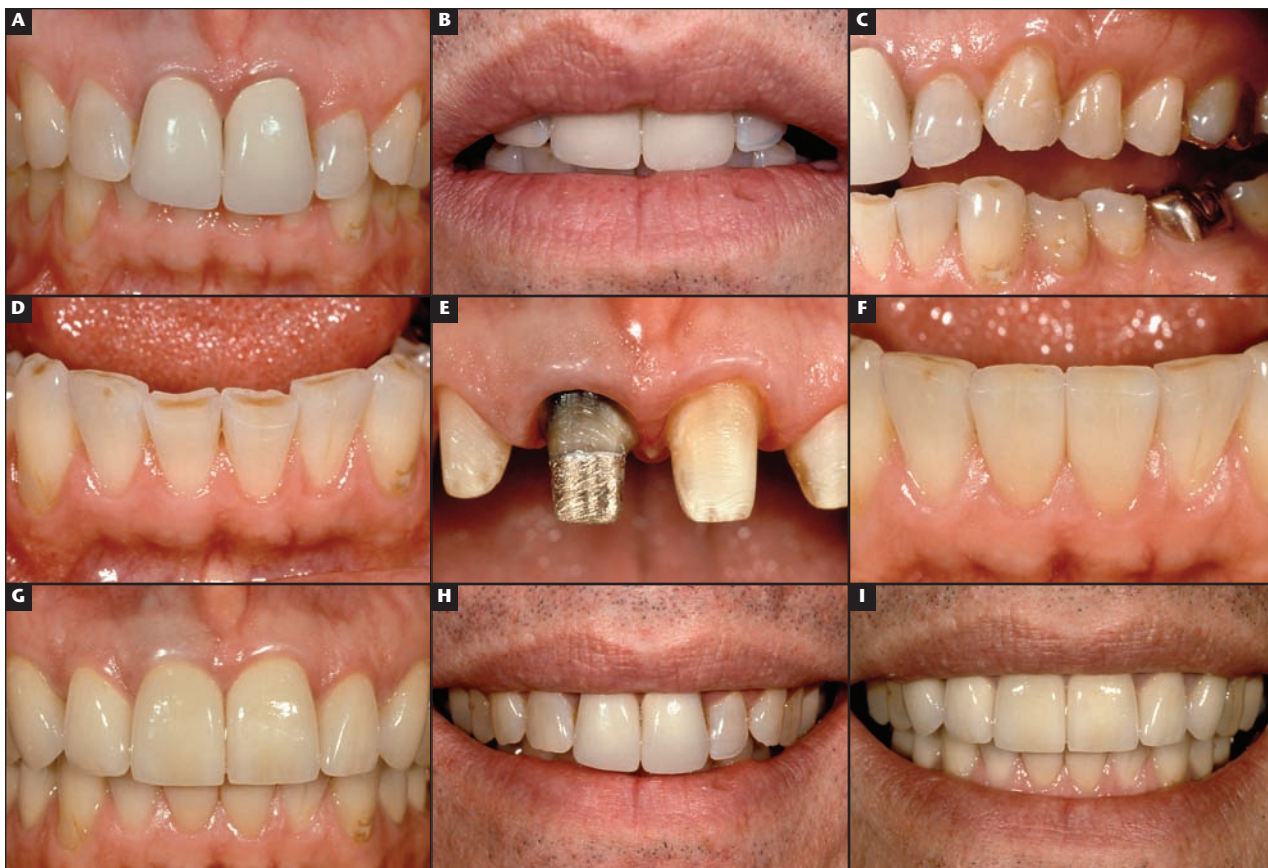

Figure 1 This man was concerned about the esthetic appearance of his maxillary anterior teeth (**A**). At rest, he showed about 4 millimeters of maxillary incisal edge (**B**). In protrusive position, he had more than sufficient incisal length to disclude the posterior teeth (**C**). Because of a protrusive bruxing habit, his mandibular incisors were worn and positioned apical to the posterior occlusal plane (**D**). The gingival margins were located correctly and the preparations had adequate ferrule (**E**). Therefore, the maxillary incisors were shortened to facilitate restoration of the mandibular incisors (**F**) and the maxillary incisors (**G**). Because the treatment was planned using esthetic principles, it was possible to improve the esthetic proportions of the teeth (**H**: before; **I**: after).

dentitions simply cannot be restored to a more esthetic appearance without the assistance of several different dental disciplines. Today, every dental practitioner must have a thorough understanding of the roles of these various disciplines in producing an esthetic makeover, with the most conservative and biologically sound interdisciplinary treatment plan possible.

We have worked in such an environment for the past 20 years. As prosthodontist, orthodontist and periodontist, we have belonged since 1984 to an interdisciplinary study group consisting of nine dental specialists and one general dentist.¹ We have met monthly since that time to educate one another about the advances in each of our respective areas of dentistry and to plan interdisciplinary treatment for some of the most challenging and complex dental situations.

One of these interdisciplinary areas is esthetics. The purpose of this article is

to provide the reader with a systematic method of evaluating dentofacial esthetics in a logical, interdisciplinary manner.

Sequencing the Planning Process

Historically, the treatment planning process in dentistry usually began with an assessment of the biology or biological aspects of a patient's dental problem. This could include the patient's susceptibility to caries, periodontal health, endodontic needs and general oral health. Once the biological health was re-established—through caries removal, modification of the bone and/or gingiva, endodontic therapy or tooth removal—then the restoration of the resulting defects would be based on structural considerations. If teeth were to be restored or repositioned, the function of the teeth and condyles would be of paramount importance in dictating occlusal form and occlusal relationships, respectively. Finally, esthetics

would be addressed to provide a pleasing appearance of the teeth.

However, if the treatment planning sequence proceeds from biology to structure to function and finally to esthetics, the eventual esthetic outcome may be compromised. Therefore, we proceed in the opposite direction: we start the treatment planning process with esthetics and proceed to function, structure and, finally, biology. We do not leave out any of the important parameters; we simply sequence the planning process from a different perspective. We choose this sequence because the decisions made in each category, especially esthetics, will directly affect the decisions made in the categories that are assessed subsequently.

Beginning With Esthetics in Mind

When beginning with esthetics, we must begin with an appraisal of the position of the maxillary central incisors relative to the upper lip (Figure 1). This

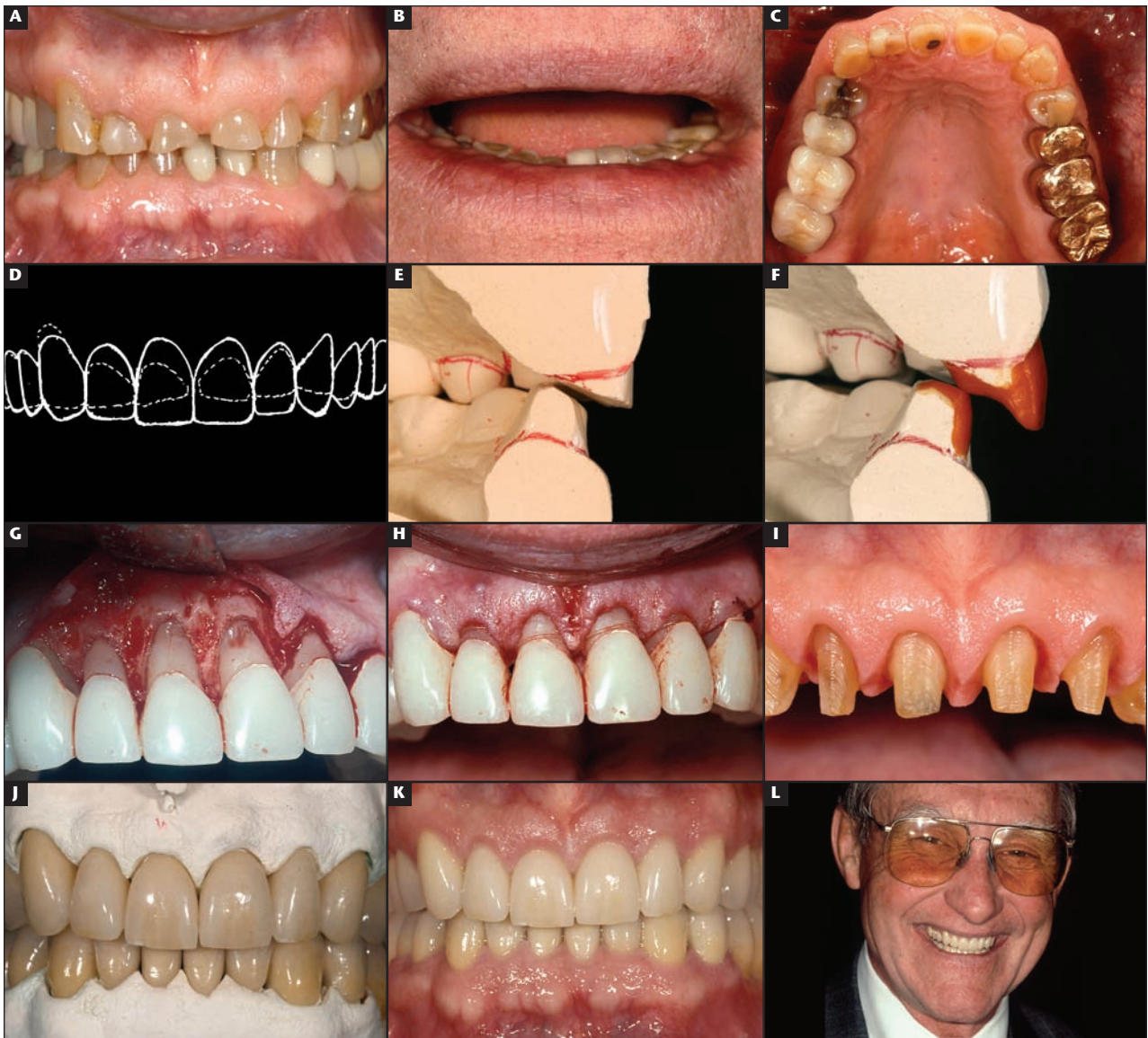


Figure 2 This man had significant wear (**A**) of his maxillary anterior teeth. His incisal edges were positioned coronal to his upper lip (**B**) at rest. The maxillary posterior teeth were restored and not worn (**C**). To determine the extent of treatment, the desired incisal edge position was estimated on the basis of the existing posterior occlusal plane (**D**). The gingival margins were estimated by means of the desired width-to-length proportions of the anterior teeth (**D**). Then a diagnostic wax-up on mounted dental casts determined whether the correction could be made without orthodontics or jaw surgery (**E,F**). The gingival margins were relocated with osseous surgery (**G,H**). Postoperatively, there was sufficient ferrule with adequate sulcus depth (**I**) to create anterior restorations with proper esthetic form (**J**). The final restoration established an improved occlusion (**K**) with enhanced anterior esthetics (**L**). Patient photograph reproduced with permission of the patient.

If the incisal edge display is inadequate, then a primary objective of interdisciplinary treatment may be to lengthen the maxillary incisal edges.

assessment is made with the patient's upper lip at rest. Using a millimeter ruler or a periodontal probe, we determine the position of the incisal edge of the maxillary central incisor relative to the upper lip. The position of the maxillary central incisor can be either acceptable or unacceptable. An acceptable amount of incisal edge display at rest depends on the patient's age. Previous studies have shown that with advancing age, the amount of incisal display decreases proportionally.^{2,3} For example, in a 30-year-old, 3 millimeters of incisal display at rest

is appropriate. However, in a 60-year-old, the incisal display could be 1 mm or less. The change in incisal display with time probably relates to the resiliency and tone of the upper lip, which tends to decrease with advancing age.

If the incisal edge display is inadequate (Figures 2 and 3), then a primary objective of interdisciplinary treatment may be to lengthen the maxillary incisal edges. This objective could be accomplished with restorative dentistry,⁴ orthodontic extrusion⁵ or orthognathic surgery.⁶⁻⁸ Choosing the correct procedure will

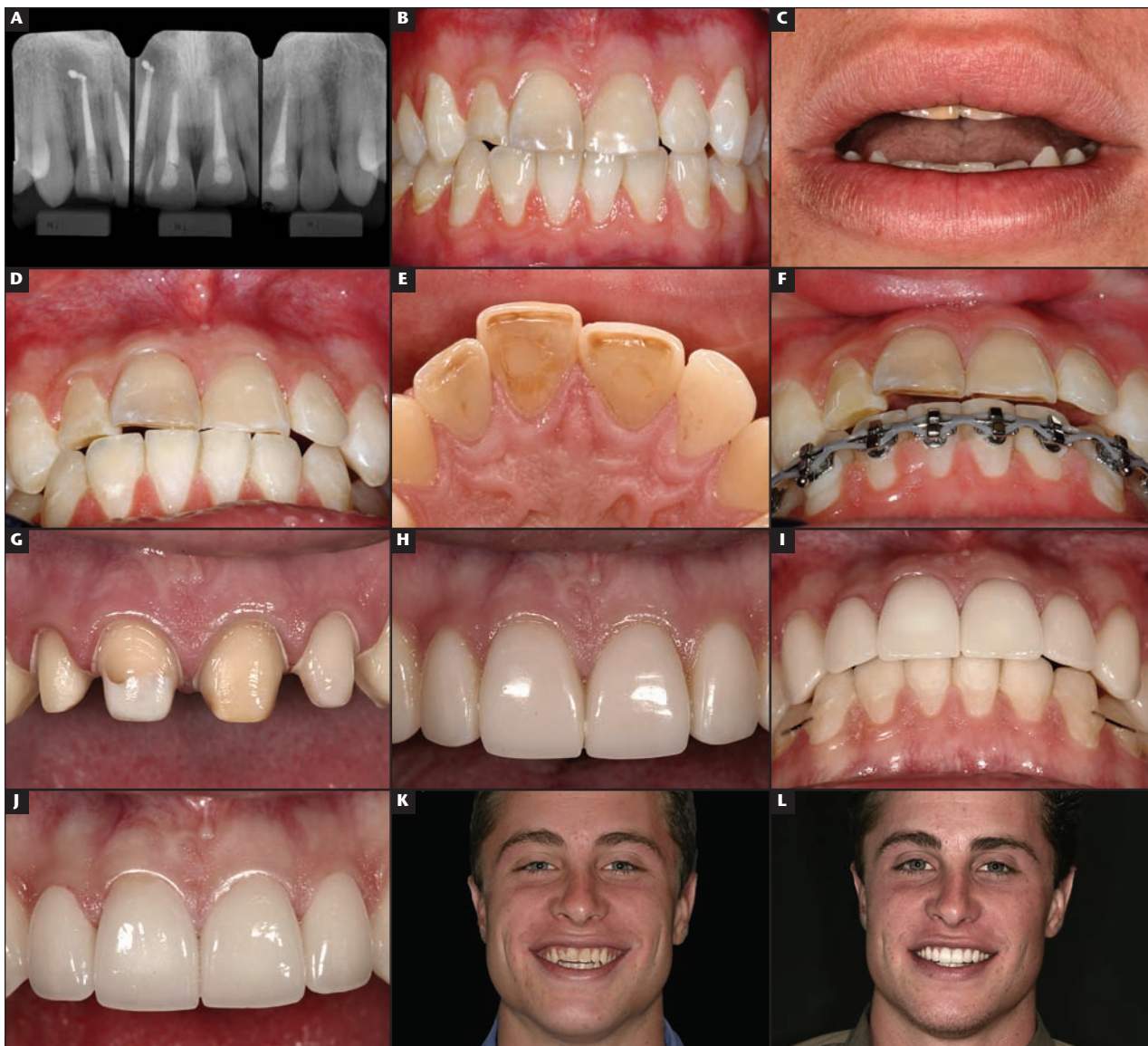

Figure 3 This man had traumatized his maxillary anterior teeth at a young age (A). These teeth were discolored (B), and the incisal edge was positioned only one millimeter from the lip at rest (C). The maxillary and mandibular incisors were in an end-to-end occlusal relationship (D), which caused further wear of the maxillary incisors (E). Orthodontic treatment was necessary to retract the mandibular incisors (F) and to facilitate preparation (G) and provisionalization of the maxillary incisors (H,I). The final restorations were placed after removal of the orthodontic appliances (J). Pretreatment (K) and post-treatment (L) photographs show the improvement in the appearance of the patient's smile. Patient photographs reproduced with permission of the patient.

depend on the patient's facial proportions, existing crown length and opposing occlusion. If the incisal edge display is excessive (Figure 1), then an objective of treatment could be to move the maxillary incisors apically by either equilibration,⁹ restoration,¹⁰ orthodontics^{11,12} or orthognathic surgery.¹³ The decision between these disciplines again will depend on the patient's existing anterior occlusion, facial proportions or both.

The second aspect of esthetic tooth positioning to be evaluated is the maxillary dental midline. If the midline is

deviated to the right or left, studies have shown that midline deviations of up to 3 or 4 mm are not noticed by lay people if the long axes of the teeth are parallel with the long axis of the face.^{14,15} So perhaps the most important relationship to evaluate is the mediolateral inclination of the maxillary central incisors. Researchers have found that if the incisors are inclined by 2 mm to the right or left, lay people regard this discrepancy as unesthetic.^{15,16} A canted midline can be corrected with orthodontics¹⁷ or restorative dentistry.¹⁸ Usually the decision

Usually the decision [between orthodontics and restorative dentistry] will depend on whether the maxillary incisors will require restoration.

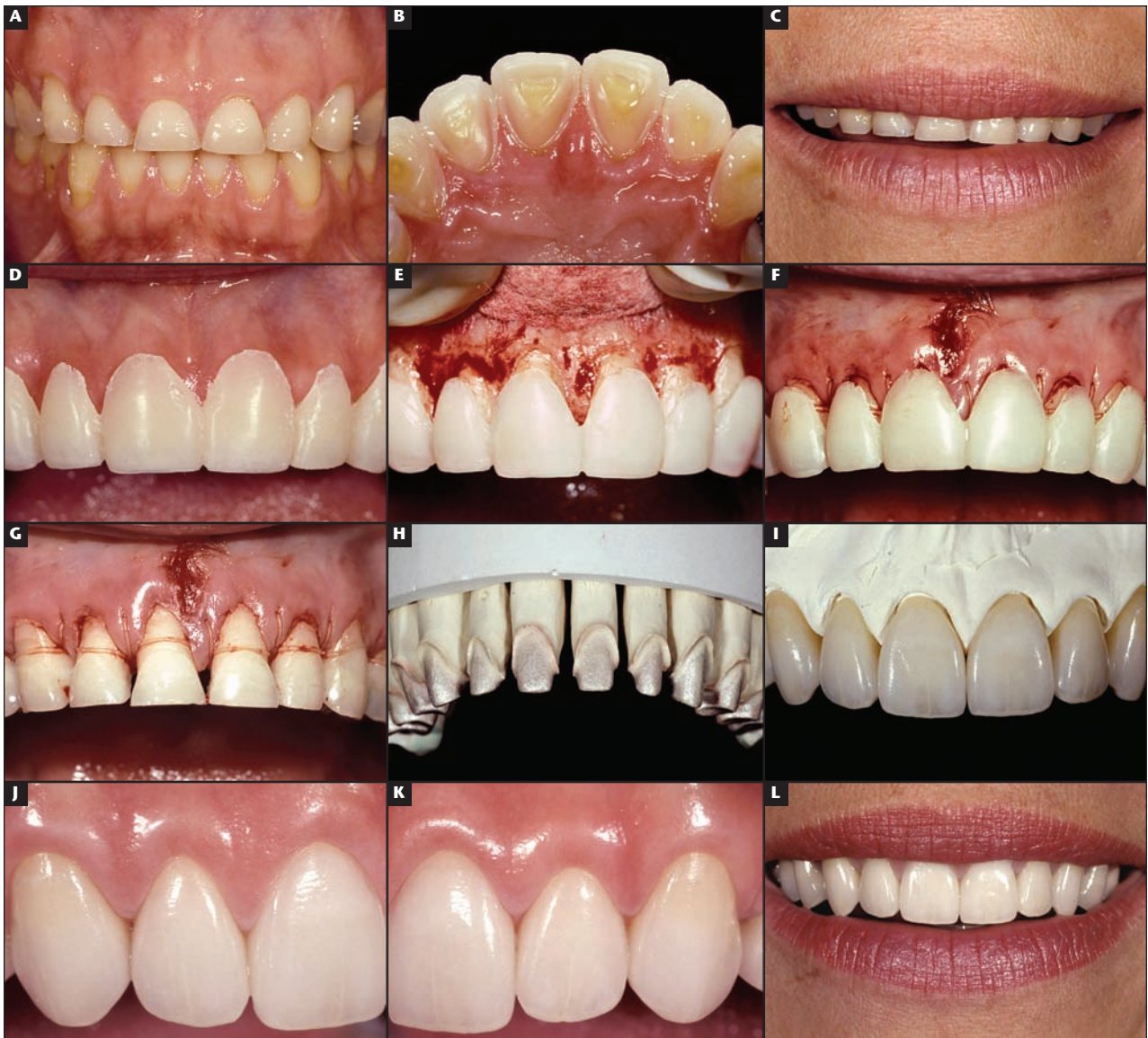

Figure 4 This woman had short maxillary incisors (**A**) and significant lingual erosion of these teeth (**B**) due to bulimia. The amount of incisal edge visible at rest was about 2 to 3 millimeters (**C**). Since the maxillary incisal edge was positioned appropriately relative to the posterior occlusal plane and her upper lip, tooth length was increased with osseous surgery. A surgical guide with proper tooth proportion (**D**) allowed the periodontist to establish the desired bone (**E**) and gingival levels (**F,G**). By increasing the crown length, adequate ferrule was available (**H**) to create esthetically proportional anterior restorations (**I**). In spite of significant crown lengthening, the tissue health after restoration was satisfactory, and the gingival margins were located properly (**J,K**), which enhanced the patient's smile.

If teeth are retroclined or proclined, correction may require either orthodontics or extensive restorative dentistry and, possibly, endodontics...

will depend on whether the maxillary incisors will require restoration.

Maxillary incisor inclination

Once we have established the correct incisal edge position and midline relationship of the maxillary incisors, the next step is to evaluate the labiolingual inclination of the maxillary anterior teeth. Are they acceptable, proclined or retroclined? When orthodontists evaluate labiolingual inclination, they rely on cephalometric radiographs to determine tooth inclination.¹⁹ However, general

dentists do not use these radiographs. Another method of assessing the inclination of the maxillary anterior teeth is to evaluate the labial surface of the existing maxillary central incisors relative to the patient's maxillary posterior occlusal plane. Generally, the labial surface of the maxillary central incisors should be perpendicular to the occlusal plane. This relationship permits maximum direct light reflection from the labial surface of the maxillary central incisors, which enhances their esthetic appearance.²⁰ If teeth are retroclined or

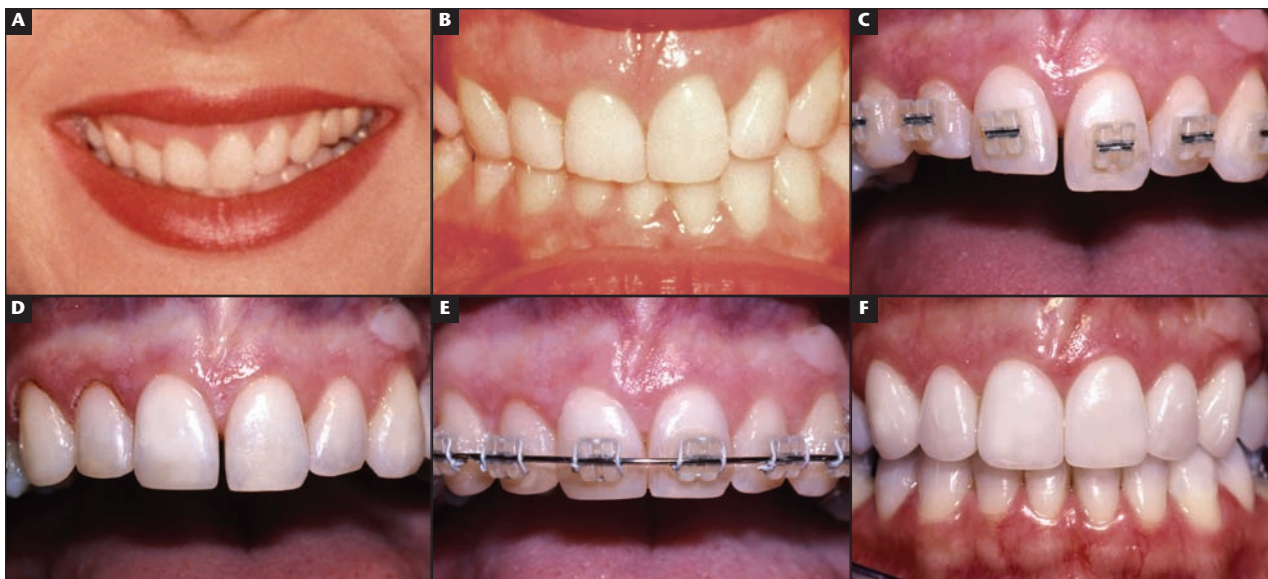


Figure 5 This woman had a cant of the gingival margins of the maxillary anterior teeth (**A**) owing to a right protrusive bruxing habit that had abraded and shortened the maxillary right central and lateral incisors and canine (**B**). The incisal edges of the maxillary anterior teeth were positioned properly relative to the upper lip and posterior occlusal plane (**B**). The maxillary right anterior teeth were intruded orthodontically (**C**) to level the gingival margins relative to the contralateral teeth. These teeth were provisionalized with composite (**D**) to stabilize them and complete the orthodontic treatment (**E**). Intrusion of the right anterior teeth facilitated the esthetic and functional restoration of the dentition (**F**).

proclined, correction may require either orthodontics or extensive restorative dentistry and, possibly, endodontics to establish a more ideal labiolingual inclination.¹⁸

The next step is to evaluate the maxillary posterior occlusal plane relative to the ideal location of the maxillary incisal edge. The maxillary incisal edge will be either level with the posterior occlusal plane (Figures 4 and 5), coronal to the posterior occlusal plane (Figure 1) or apical to the posterior occlusal plane (Figures 2 and 3). Correcting the posterior occlusal plane position will require orthognathic surgery,^{21,22} restorative dentistry or both.¹⁸ The amount of tooth abrasion, the patient's vertical facial proportions and the position of the alveolar bone will help determine the correct solution of posterior occlusal plane discrepancies.

After the position of the maxillary central incisal edges have been determined, the incisal edges of the maxillary lateral incisors and canines, as well as of the buccal cusps of the maxillary premolars and molars, can be established (Figure 2). The levels of these teeth generally are determined by their esthetic relationship to the lower lip when the patient smiles.^{23,24} If the patient has an asymmetric lower lip, then it may be more prudent to use the

interpupillary line as a guide in establishing the posterior occlusal plane.²⁵

Determining gingival levels

The next step in the process of determining the esthetic relationship of the maxillary anterior teeth is to establish the gingival levels. The gingival levels should be assessed relative to the projected incisal edge position. The key to determining the correct gingival levels is to determine the desired tooth size relative to the projected incisal edge position (Figures 2, 4 and 5). It is important to remember that the incisal edge is not positioned to create the correct tooth size relative to the gingival margin levels. Using the gingiva as a reference to position the incisal edges is risky, because gingiva can move with eruption or recession. Therefore, the ideal gingival levels are determined by establishing the correct width-to-length ratio of the maxillary anterior teeth,²⁶⁻²⁸ by determining the desired amount of gingival display¹⁵ and by establishing symmetry between right and left sides of the maxillary dental arch.¹⁸

If the existing gingival levels will produce a tooth that is too short relative to the projected incisal edge position, then the gingival margins must be moved apically. This adjustment can be

The key to determining the correct gingival levels is to determine the desired tooth size relative to the projected incisal edge position.

Remember, the more alterations one makes [to tooth shape or tooth shade], the more teeth one will be treating and the more involved the treatment plan will become.

accomplished by means of either gingival or osseous surgery,^{29,30} orthodontic intrusion,¹¹ or orthodontic intrusion and restoration.³¹⁻³³ The key factors that determine the most appropriate method of correction include the sulcus depth, the location of the cementoenamel junction relative to the bone level, the amount of existing tooth structure, the root-to-crown ratio and the shape of the root.³⁴ In some situations, it is more appropriate to lengthen the crowns of the maxillary incisors surgically (Figures 2 and 4) to establish the correct gingival levels.¹⁰ In other situations, orthodontic intrusion (Figure 5) and restoration of the incisal edge is more appropriate.³⁴

The next step in the process of establishing the correct esthetic position of the maxillary anterior teeth is to assess the papilla levels relative to the overall crown length of the maxillary central incisors. Research has shown that the average ratio is about 50 percent contact and 50 percent papilla.³⁵ If the contact is significantly shorter than the papilla (Figures 2 and 4), it usually indicates moderate-to-significant incisor abrasion, which tends to shorten the crowns and, therefore, shortens the contact between the central incisors.³⁰ If the contact is significantly longer than the papilla, it could suggest that the gingival contour or scallop over the central incisors is flat, which could be caused by altered passive or altered active eruption of the teeth.³⁶ Either gingival or osseous surgery¹⁰ or orthodontic intrusion¹³ or extrusion³⁴ may be necessary to correct the level of the papillae between the maxillary anterior teeth.

Arrangement, contour and shade

The clinician now has established the incisal edge position, the midline, the axial inclination, the gingival margins and the papillary levels of the maxillary anterior teeth. The next step is to determine if the arrangement of the maxillary anterior teeth can be accomplished restoratively—and if not, whether the patient will require orthodontics to facilitate restoration. If in doubt, the clinician should perform a diagnostic wax-up (Figure 2) to confirm whether

the arrangement is possible restoratively.^{18,34,37} In addition, the contour and shade of the anterior teeth must be addressed. Does the patient have any specific requests concerning tooth shape or tooth shade? Remember, the more alterations one makes in these parameters, the more teeth one will be treating and the more involved the treatment plan will become. A good guide to esthetic treatment planning is to determine the ideal endpoint of treatment, then compare it with the patient's current condition. Treatment is indicated when the desired endpoint and the current condition do not match. The actual method of treatment then can be chosen on the basis of the magnitude of the difference.

Developing the esthetic plan for the mandibular teeth

Now that the esthetic relationship of the maxillary incisors has been established, the mandibular incisors must relate to the maxillary tooth position. First, evaluate the level of the mandibular incisal edges relative to the face. Do they have acceptable display or excessive display, or are they not visible at all? If they have excessive display, equilibration, restoration or orthodontic intrusion are possible methods of correcting the problem.³⁴ If they are not visible, either restoration or orthodontic extrusion may be necessary.^{38,39} Next, determine the relationship of the mandibular incisors relative to the posterior occlusal plane. Are the incisors level with the posterior occlusal plane? If not, then they are either coronal or apical to the posterior occlusal plane. Correcting either of these relationships could require restoration (Figure 1), equilibration or orthodontics.⁴ Finally, the labiolingual inclination of the mandibular incisors must be evaluated. This relationship is determined partially by the projected position of the maxillary incisors. If the inclination is either proclined (Figure 3) or retroclined, orthodontics could be a useful adjunct in adjusting the labiolingual position of the mandibular incisors.³⁴ The final mandibular incisal edge position usually is determined during the functional and

structural phases of the treatment planning (Figures 2-5).

The gingival levels of the mandibular dentition may need to change when the different options for leveling the mandibular occlusal plane are considered. If orthodontics is selected to either intrude or extrude teeth, the gingival margins will move with the teeth.⁴⁰ However, if equilibration, restoration or both are necessary to level the mandibular occlusal plane, then the gingival levels may need to be relocated with osseous surgery.¹⁰

At this point, based on the esthetic determination of the projected positions of the maxillary and mandibular teeth, the clinician should be able to determine which teeth will need restoration⁴¹—that is, the maxillary anterior, maxillary posterior, mandibular anterior and/or mandibular posterior teeth. Then, once the maxillary and mandibular occlusal planes have been established through esthetic parameters, the clinician must determine how to create an acceptable occlusal relationship between the arches.

Steps to Integrating Function and Esthetics

The first step to integrating the esthetic plan with the functioning occlusion is to evaluate the temporomandibular joints and muscles.⁴² Does the patient have any joint or muscle symptoms? A key step in the process of diagnosing the cause of such symptoms is to make centric relation records and mount the models. Our definition of centric relation is the position of the condyles when the lateral pterygoid muscles are relaxed and the elevator muscles contact with the disk properly aligned.⁴² The question that the clinician must ask is whether the desired esthetic changes can be made without altering the occlusion. If not, orthodontics, orthognathic surgery or both may be required to correct tooth position to facilitate the esthetic positioning of the teeth. To determine the impact of the esthetic plan on the function or occlusion, the esthetic changes in maxillary tooth position must be transferred to the maxillary dental cast.⁴² This is accomplished with a combination

of wax and adjustment of the plaster casts (Figure 2).

As the proposed esthetic treatment plan is transferred to the mounted casts, the clinician will be able to determine if only restoration will accomplish the desired occlusion, or if alteration of the occlusal scheme through orthodontics, orthognathic surgery or both will be necessary. This is especially true when the clinician is planning to level the occlusal planes. A key question to ask is whether leveling of the occlusal planes creates an acceptable anterior dental relationship. If the answer is yes and the leveling would involve only the mandibular incisors, then the patient's existing vertical dimension can be maintained. If, however, the answer is no or the leveling would involve mandibular posterior teeth, the existing vertical dimension may need to be altered. The clinician must determine whether altering the vertical dimension will result in acceptable tooth form and anterior relationships. There is no replacement for mounted dental casts and a diagnostic wax-up when these critical questions are being addressed.

Determining if Adequate Structure Exists for Tooth Restoration

Once the esthetic treatment plan has been established, the projected tooth position has been verified on the diagnostic wax-up and the functional relationships of the mounted dental casts have been assessed, the clinician must determine if adequate tooth structure exists to allow for restoration of the teeth. If not, how will the clinician attain adequate structure? What types of restorations will be placed? How will they be retained? How will any missing teeth be replaced? Depending on the clinician's assessment of the remaining tooth structure,⁴¹ the choices for restoring anterior teeth could include composite bonding, porcelain veneers, bonded all-ceramic crowns, luted all-ceramic crowns or metal ceramic crowns. The posterior restorations could include direct restorations, inlays, onlays or crowns. If teeth are missing, they will be replaced with either

Once the esthetic treatment plan has been established... the clinician must determine if adequate tooth structure exists to allow for restoration of the teeth.

The primary objective of biological treatment planning is to establish a healthy oral environment with the tissue in the desired location.

implants, fixed partial dentures or removable partial dentures. The criteria to evaluate to determine which restorations are appropriate include

- the clinical crown length;
- the crown length after any gingival changes are performed for esthetic reasons;
- the amount of ferrule⁴⁰;
- whether there is sufficient space for a buildup;
- how any crown lengthening needed for structural purposes will affect the esthetics (Figures 2-5).

The methods for increasing the retention of restorations are buildup, surgical crown lengthening,¹⁰ orthodontic forced eruption^{33,40} and bonding of the restoration. Each clinical situation must be evaluated carefully to determine the appropriate structural solution.

Biology: Last but Certainly Not Least

The esthetic plan has been established. The diagnostic wax-up confirms that the teeth will function properly. The restorative plan has taken into consideration the existing tooth structure. Now is the time to add the biological aspects of the treatment plan.

The biological aspects include any need for endodontic care, periodontic care or orthognathic surgery. The primary objective of biological treatment planning is to establish a healthy oral environment with the tissue in the desired location. To accomplish this objective, the clinician may need to perform endodontic procedures on teeth that are salvageable structurally and periodontally. In these cases, the endodontic therapy must be completed first, before the restorative phase of dentistry begins. The definitive periodontal therapy must be established to create a healthy periodontium based on the esthetic, functional and structural needs of the restorations. Any elective periodontics must be completed next, in conjunction with the restorative plan. Finally, if there are any skeletal abnormalities that require orthognathic surgical correction, these must be accomplished before the definitive restorative phase of treatment.

Sequencing the Therapy

The plan is complete. It began with esthetics, it was correlated to function, it took into consideration the remaining tooth structure, and it was facilitated by recognition of the biological needs of the patient. The only two questions that remain are

- how to sequence this esthetically based treatment plan;
- whether the patient can afford the treatment.

The sequence of any treatment plan always should begin with the management or alleviation of acute problems. Then the remaining treatment plan can be sequenced in a manner that seems the most logical and facilitates the next or following phase of treatment, provided the result can be identified clearly, communicated and achieved for the pertinent phase. When we establish the sequence of treatment for an interdisciplinary patient, we list the steps in the treatment plan based on our collective opinion before treatment begins.^{34,37} Every member of the team receives a copy of the written treatment sequence. This step ensures that each member of the team will be able to follow the steps in the esthetic, functional, structural and biological rehabilitation of our mutual dental patient.

Patient type

The economics of the interdisciplinary esthetic treatment plan obviously is of primary importance. In a previous article,⁴³ the types of patients in the modern dental practice have been divided into four types (I, II, III and IV). Patients of types I and II generally do not require significant esthetic restoration. However, those of types III and IV typically will require the type of esthetic evaluation that we have outlined in this article.

The type III patient is a healthy adult with no occlusal disease and no periodontal problems but a desire for an esthetic change (Figure 1). The type III patient could be described as the esthetic patient, one who is dentally healthy but wishes to make a change in appearance. The hallmark of treating the true

esthetic patient is the requirement of time on the part of the dentist.

The most challenging situation is the type IV patient (Figures 2-5), whom we have described in this article. This is an adult whose dentition is failing and who may have occlusal disease, periodontal disease, multiple restorative needs and missing teeth. The type IV patient is the complex reconstruction patient in any dental practice. The hallmark of this patient is multiple appointments over months or even years, depending on his or her orthodontic, periodontal, endodontic, surgical and restorative needs. Owing to the increased number of appointments and laboratory fees, the clinician must adjust the fees to reflect the amount of time commitment. For ideas on establishing appropriate fees in these types of patients, the reader is referred to a previous article.⁴³

Summary

Esthetics has become a respectable concept in dentistry. In the past, the importance of esthetics was discounted in favor of concepts such as function, structure and biology. But in fact if a treatment plan does not begin with a clear view of its esthetic impact on the patient, then the outcome could be disastrous. In today's interdisciplinary dental world, treatment planning must begin with well-defined esthetic objectives. By beginning with esthetics and then taking into consideration the impact of the planned treatment on function, structure and biology, the clinician will be able to use the various disciplines in dentistry to deliver the highest level of dental care to each patient. We call this process "interdisciplinary esthetic dentistry," and it really works.

References

1. Spear FM. My growing involvement in dental study groups. *J Am Coll Dent* 2002;69(4):22-4.
2. Vig RG Brundo GC. The kinetics of anterior tooth display. *J Prosthet Dent* 1978;39:502-504.
3. Ackerman MB, Brensinger C, Landis JR. An evaluation of dynamic lip-tooth characteristics during speech and smile in adolescents. *Angle Orthod* 2004;74(1):43-50.
4. Spear F, Kokich VG, Mathews D. An interdisciplinary case report. *Esthet Interdisc Dent* 2005;1(2):12-8.
5. Lopez-Gavito G, Wallen TR, Little RM, Joondeph DR. Anterior open-bite malocclusion: a longitudinal 10-year postretention evaluation of orthodontically treated patients. *Am J Orthod* 1985;87(3):175-86.
6. de Mol van Otterloo JJ, Tuinzing DB, Kostense P. Inferior positioning of the maxilla by a Le Fort I osteotomy: a review of 25 patients with vertical maxillary deficiency. *J Craniomaxillofac Surg* 1996;24(2):69-77.
7. Major PW, Philippson GE, Glover KE, Grace MG. Stability of maxilla downgrafting after rigid or wire fixation. *J Oral Maxillofac Surg* 1996;54:1287-91.
8. Costa F, Robiony M, Zerman N, Zorzan E, Politi M. Bone biological plate for stabilization of maxillary inferior repositioning. *Minerva Stomatol* 2005;54:227-36.
9. Kokich VG. Maxillary lateral incisor implants: planning with the aid of orthodontics. *J Oral Maxillofac Surg* 2004;62(9 supplement 2):48-56.
10. Spear F. Construction and use of a surgical guide for anterior periodontal surgery. *Contemp Esthet Restor Pract* 1999 April:12-20.
11. Kokich V. Esthetics and anterior tooth position: an orthodontic perspective, part II: vertical position. *J Esthet Dent* 1993;5(4):174-8.
12. Nanda R. Correction of deep overbite in adults. *Dent Clin North Am* 1997;41(1):67-87.
13. Kokich VG, Spear FM, Kokich VO. Maximizing anterior esthetics: an interdisciplinary approach. In: McNamara JA Jr, ed. *Frontiers in dental and facial esthetics*. Ann Arbor, Mich.: Needham Press; 2001:1-18.
14. Beyer JW, Lindauer SJ. Evaluation of dental midline position. *Semin Orthod* 1998;4(3):146-152.
15. Kokich VO, Kiyak HA, Shapiro PA. Comparing the perception of dentists and lay people to altered dental esthetics. *J Esthet Dent* 1999;11:311-324.
16. Thomas JL, Hayes C, Zawaideh S. The effect of axial midline angulation on dental esthetics. *Angle Orthod* 2003;73:359-364.
17. Kokich VG. Esthetics and anterior tooth position: an orthodontic perspective, part III: mediolateral relationships. *J Esthet Dent* 1993;5:200-7.
18. Spear FM. The esthetic correction of anterior dental malalignment: conventional vs. instant (restorative) orthodontics. *J Calif Dent Assoc* 2004;32(2):133-141.
19. Littlefield K. A review of the literature of selected cephalometric analyses. St. Louis: University Press; 1992.
20. Rufenacht C. Fundamentals of esthetics. Carol Stream, Ill.: Quintessence; 1990.
21. Denison TF, Kokich VG, Shapiro PA. Stability of maxillary surgery in openbite versus nonopenbite malocclusions. *Angle Orthod* 1989;59(1):5-10.
22. Proffit WR, Bailey LJ, Phillips C, Turvey TA. Long-term stability of surgical open-bite correction by Le Fort I osteotomy. *Angle Orthod* 2000;70(2):112-7.
23. Naylor CK. Esthetic treatment planning: the grid analysis system. *J Esthet Restor Dent* 2002;14(2):76-84.
24. Van der Geld PA, van Waas MA. The smile line: a literature search [in Dutch]. *Ned Tijdschr Tandheelkd* 2003;110:350-4.
25. Chiche G, Kokich V, Caudill R. Diagnosis and treatment planning of esthetic problems. In: Pinault A, Chiche G, eds. *Esthetics in fixed prosthodontics*. Chicago: Quintessence; 1994.
26. Gillen RJ, Schwartz RS, Hilton TJ, Evans DB. An analysis of selected normative tooth proportions. *Int J Prosthodont* 1994;7:410-7.
27. Sterrett JD, Oliver T, Robinson F, Fortson W, Knaak B, Russell CM. Width/length ratios of normal clinical crowns of the maxillary anterior dentition in man. *J Clin Periodontol* 1999;26(3):153-7.
28. Wolfart S, Thormann H, Freitag S, Kern M. Assessment of dental appearance following changes in incisor proportions. *Eur J Oral Sci* 2005;113(3):159-65.
29. Kokich VG. Esthetics: the ortho-perio-restorative connection. *Semin Orthod* 1996;2(1):21-30.
30. Kokich VG, Kokich VO. Orthodontic therapy for the periodontal-restorative patient. In: Rose L, Mealey B, Genco R, Cohen D, eds. *Periodontics: Medicine, surgery, and implants*. St. Louis: Mosby-Elsevier; 2004:718-44.
31. Kokich VG. Anterior dental esthetics: an orthodontic perspective I: crown length. *J Esthet Dent* 1993;5:19-23.
32. Kokich VG. Esthetics and vertical tooth position: the orthodontic possibilities. *Compendium Cont Ed Dent* 1997;18:1225-31.
33. Kokich VG. Managing orthodontic-restorative treatment for the adolescent patient. In: McNamara JA Jr, ed. *Orthodontics and dentofacial orthopedics*. Ann Arbor, Mich.: Needham Press; 2001:395-422.
34. Kokich VG, Kokich VO. Interrelationship of orthodontics with periodontics and restorative dentistry. In: Nanda R, ed. *Biomechanics and esthetic strategies in clinical orthodontics*. St. Louis: Elsevier; 2005:348-73.
35. Kurth JR, Kokich VG. Open gingival embrasures after orthodontic treatment in adults: prevalence and etiology. *Am J Orthod Dentofacial Orthop* 2001;120(2):116-23.
36. Spear F. Maintenance of the interdental papilla following anterior tooth removal. *Pract Periodontics Aesthet Dent* 1999;11(1):21-8.
37. Kokich VG, Spear F. Guidelines for treating the orthodontic-restorative patient. *Semin Orthod Dentofacial Orthop* 1999;3:3-20.
38. Emerich-Poplatek K, Sawicki L, Bodal M, Adamowicz-Klepalska B. Forced eruption after crown/root fracture with a simple and aesthetic method using the fractured crown. *Dent Traumatol* 2005;21(3):165-9.
39. Koyuturk AE, Malkoc S. Orthodontic extrusion of subgingivally fractured incisor before restoration: a case report—3-years follow-up. *Dent Traumatol* 2005;21(3):174-8.
40. Spear F. When to restore, when to remove. *Insight Innovation* 2001:29-37. Available at: "www.seattleinstitute.com/content/articles/B%26WWhentoRestoreWhentoRemove.pdf". Accessed Jan. 5, 2006.
41. Spear F. A conversation with Dr. Frank Spear. *Dent Pract Rep* March 2002; 42-8.
42. Spear F. Occlusion in the new millennium: the controversy continues. *Signature* 2002;7:18-21.
43. Spear F. Implementing the plan: the economics of restorative dentistry. *Insight Innovation* 2001:33-40. Available at: "www.seattleinstitute.com/content/articles/ImplementingthePlanTheEconomicsOfRestorativeDentistry.pdf". Accessed Jan. 5, 2006.

Continuing Education Quiz

Loma Linda University School of Dentistry provides 1 hour of Continuing Education credit for this article for those who wish to document their continuing education efforts. To participate in this CE lesson, please log on to **www.AEID.AEGISCE.net**, where you may further review this lesson and test online for a fee of \$14.00. To obtain mailing instructions or for more information, please call 877-4-AEGIS-1.

1. **Historically, the treatment planning process assessed the following in which order?**
 - a. function, biology, esthetics, structural
 - b. biology, structural, function, esthetics
 - c. structural, function, biology, esthetics
 - d. esthetics, biology, function, structural
2. **When assessing the position of the maxillary central incisor, an acceptable amount of incisal edge display at rest depends on:**
 - a. how high the patient's lip line is.
 - b. the patient's periodontal status.
 - c. the patient's age.
 - d. whether the patient can occlude completely.
3. **Studies have shown that midline deviations of up to what amount are not noticed by lay people if the long axes of the teeth are parallel with the long axis of the face?**
 - a. 1 or 2 mm
 - b. 2 or 3 mm
 - c. 3 or 4 mm
 - d. 4 or 5 mm
4. **Generally, what surface of the maxillary central incisors should be perpendicular to the occlusal plane?**
 - a. occlusal
 - b. lingual
 - c. labial
 - d. facial
5. **What characteristics will help determine the correct solution of posterior occlusal plane discrepancies?**
 - a. the amount of tooth abrasion
 - b. the patient's vertical facial proportions
 - c. the position of the alveolar bone
 - d. all of the above
6. **It may be more prudent to use the interpupillary line as a guide in establishing the posterior occlusal plane if the patient has what?**
 - a. an asymmetric lower lip
 - b. an asymmetric upper lip
 - c. a symmetric lower lip
 - d. a symmetric upper lip
7. **When assessing the papilla levels relative to the overall crown length of the maxillary central incisors, research has shown that the average ratio is about:**
 - a. 30 percent contact and 70 percent papilla.
 - b. 40 percent contact and 60 percent papilla.
 - c. 50 percent contact and 50 percent papilla.
 - d. 60 percent contact and 40 percent papilla.
8. **If the level of the mandibular incisal edges relative to the face have excessive display, which of the following options are possible methods of correcting the problem?**
 - a. equilibration
 - b. restoration
 - c. orthodontic intrusion
 - d. all of the above
9. **The first step to integrating the esthetic plan with the functioning occlusion is to evaluate what?**
 - a. the density of the bone structure
 - b. the temporomandibular joints and muscles
 - c. the alignment of the jaw
 - d. the periodontal status of the patient
10. **If leveling of the occlusal planes creates an acceptable anterior dental relationship, the patient's existing vertical dimension can be maintained by leveling only the:**
 - a. mandibular incisors.
 - b. maxillary incisors.
 - c. mandibular bicuspid.
 - d. maxillary bicuspid.



Loma Linda University
School of Dentistry
Continuing Dental Education

ADAC•E•R•P®
CONTINUING EDUCATION RECOGNITION PROGRAM

Loma Linda University
School of Dentistry
is an ADA CERP
and
ACDE
recognized provider

