

Esthetics and Vertical Tooth Position: Orthodontic Possibilities

CE 3

Abstract: Throughout the 1990s, esthetic dentistry has become a prominent part of the treatment protocol of most dentists. Patients have become more conscious of the benefits of a beautiful smile and are willing to invest time and money to improve the appearance of their teeth. Many of these patients can be treated with routine restorative procedures (crowns, composites, laminates) to achieve the desired results. However, some patients have problems with tooth position that create significant discrepancies in gingival levels which can compromise the esthetic result of restorative dentistry. Prerestorative orthodontic therapy can often resolve these tooth position problems and enhance the esthetic restoration. This article describes the indication, methods, and results achieved when orthodontics preceded restorative dentistry in the treatment of various esthetic challenges.

Vincent G. Kokich, DDS

Professor

Department of Orthodontics

University of Washington School of Dentistry
Seattle, Washington

Learning Objectives:

After reading this article, the reader should be able to:

- determine which restorative situations can benefit from vertical orthodontic repositioning.
- describe treatment options for correcting a "gummy smile."
- explain the importance of allowing sufficient time for the teeth to stabilize after completion of the intrusion/extrusion process.
- identify the appropriate treatment for correctly discrepancies in gingival levels.

The objectives of restorative dentistry are to improve oral health, to establish proper occlusal function, and to create ideal esthetics. These objectives are difficult to achieve in some patients because of tooth malposition. Supereruption, crowding, trauma, and severe bruxism may produce vertical discrepancies of the anterior teeth that are impossible for the restorative dentist to correct with tooth preparation and restoration alone.

Periodontal surgery is often helpful as an adjunct to restorative treatment, for instance, to improve gingival margin relationships in the maxillary anterior region. But in some situations, periodontal surgery may be a less-than-ideal treatment option, perhaps even contraindicated. In these cases, vertical orthodontic repositioning may be an appropriate alternative for relocating gingival margins around anterior teeth before restorative treatment.¹⁻³ Through five case presentations, this article discusses the kinds of restorative situations that can benefit from prerestorative orthodontic positioning and describes the interdisciplinary steps needed to achieve an ideal result.

Case Studies

Case 1

This 42-year-old woman disliked the irregular appearance of her maxillary anterior teeth and wanted to restore the teeth to more ideal esthetics. She had moderate crowding of the incisors, and the two central incisors were overlapped (Figure 1A). Because of the long-standing tooth malposition and a protrusive bruxing habit, the patient had abraded the maxillary incisal edges, and the right central incisor, which was positioned lingually, had become shorter than the left central incisor.

One possible treatment for correcting the crowding and improving esthetics was to place porcelain or resin veneers on the labial surfaces of the four incisors. However, the right central incisor would still be shorter than the left central incisor because of a gingival margin discrepancy. A simple excisional gingivectomy would not correct the discrepancy because the patient's sulcular depth labial to the right and left central incisors was identical. To achieve ideal gingival levels, a flap procedure with bone removal would be necessary. This

would be disadvantageous because it could expose part of the root cementum and complicate the restorative process.

A second, and less destructive, alternative would be to intrude the right central incisor orthodontically. This could relocate the gingival margin apically to match the gingival mar-

Figure 1A—This patient had overlapped maxillary central incisors and uneven gingival margins.

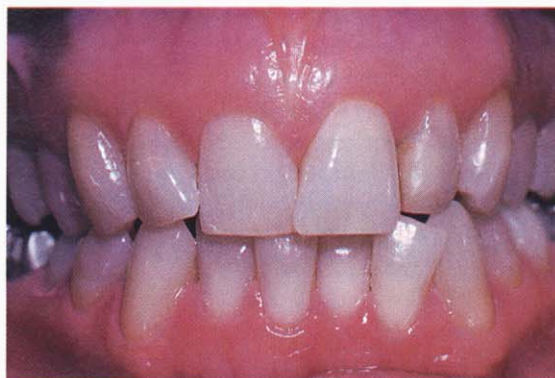

Figure 1B—Orthodontic brackets were positioned to intrude the right central incisor.

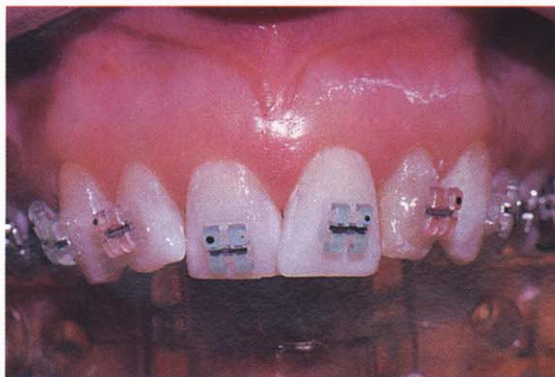

Figure 1C—The goal of orthodontic movement was to level the gingival margins of the central incisors and not to align the incisal edges.

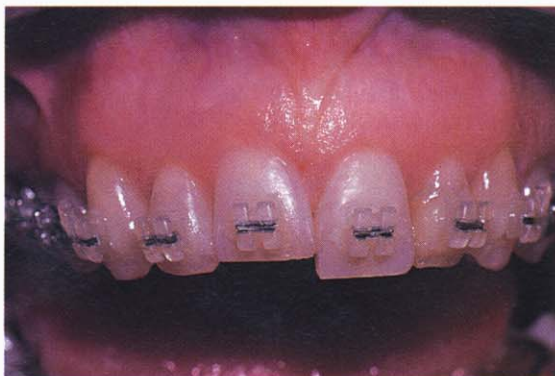
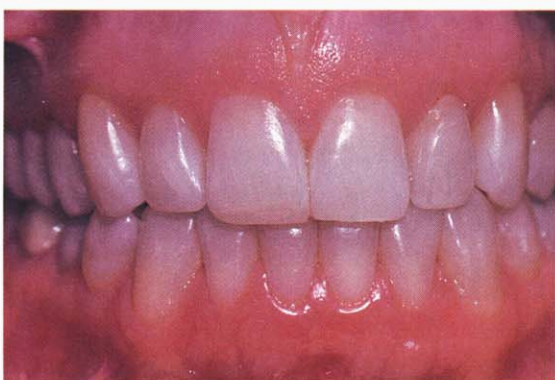
Figure 1D—After orthodontic treatment, the incisal edge of the right central incisor was restored to re-create proper crown length to match the left central incisor.



gin of the left central incisor. Because the right central incisor will be restored anyway (to re-create proper length), vertical repositioning of the tooth orthodontically means the restorative dentist can add length to the tooth during the veneering process. Another advantage of this treatment plan is that there would be less need to restore all the maxillary incisors.

If the restorative dentist and orthodontist adopt this mode of therapy, it is important to place the orthodontic brackets properly at the outset (Figure 1B) so the teeth will begin intruding early in the treatment process. After the gingival margins have been leveled (Figure 1C), the restorative dentist can place a temporary composite restoration on the incisal edge of the intruded right central incisor to eliminate the vertical discrepancy until the final porcelain veneer has been fabricated (Figure 1D). This interdisciplinary treatment is less destructive to the adjacent teeth and may eliminate the need for surgical crown lengthening in many patients.

Case 2

This 46-year-old patient disliked her "gummy smile." When she smiled broadly, she showed 4 mm of gingiva apical to the gingival margins of the maxillary incisors (Figure 2A). In addition, her maxillary incisors were significantly abraded because of a protrusive bruxing habit. The maxillary central incisors were square in shape, rather than rectangular, because of excessive wear of the incisal edges. This patient's goals were to improve the esthetic appearance of her maxillary incisors and to eliminate her "gummy smile."

Orthognathic surgery could be performed to intrude the maxilla, thus eliminating the excessive gingival display, but it also would shorten the patient's facial height. An alternative would be surgical crown-lengthening of the maxillary incisors. A flap could be elevated, bone could be removed, and the gingival margins could be positioned apically. This would create longer crowns and eliminate the "gummy smile," but it would reduce the crown-to-root ratio and possibly open "black triangles" between all of the maxillary incisors. A third option would be orthodontic intrusion of the central incisors. This plan would not shorten the crown-to-root ratio, thus avoiding the creation of "black triangles," and it would eliminate the need for jaw surgery or periodon-

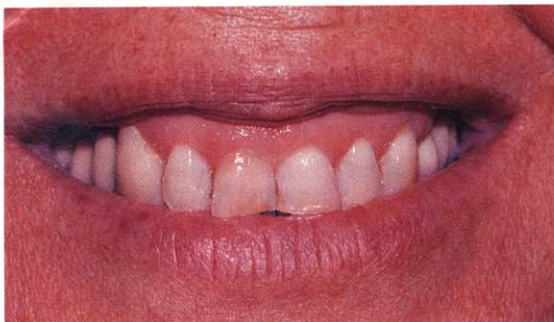

Figure 2A—This patient had a “gummy smile” and short, abraded maxillary central incisors from a protrusive bruxing habit.

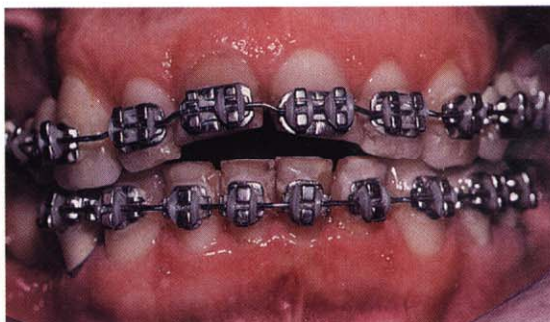

Figure 2B—To create space that would allow lengthening of the central incisor crowns, the patient's maxillary incisors were intruded orthodontically.

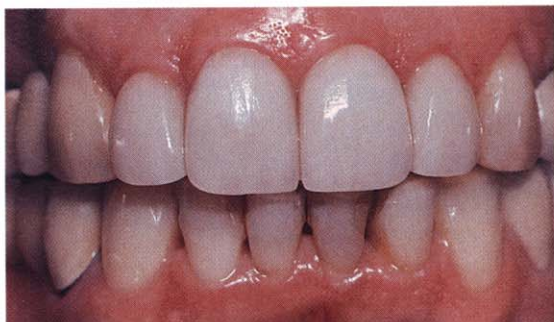

Figure 2C—Tooth intrusion permitted construction of longer and more esthetically shaped central and lateral incisor crowns.

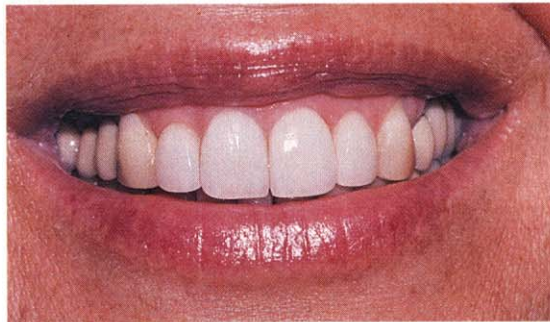

Figure 2D—The orthodontic-restorative treatment eliminated the patient's “gummy smile.”

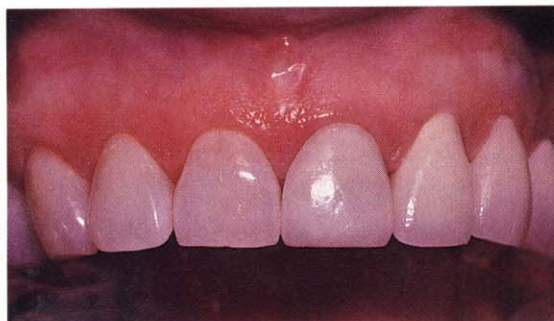


Figure 3A—This patient was missing her maxillary left canine and first premolar and had a 10-year-old bridge extending from the left lateral incisor to the second premolar. In addition, she disliked the length of her lateral incisor crown.

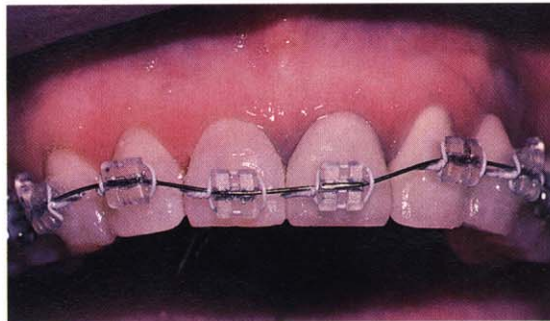

Figure 3B—To align gingival levels before reconstruction of the bridge, orthodontic brackets were intentionally placed in unusual positions.

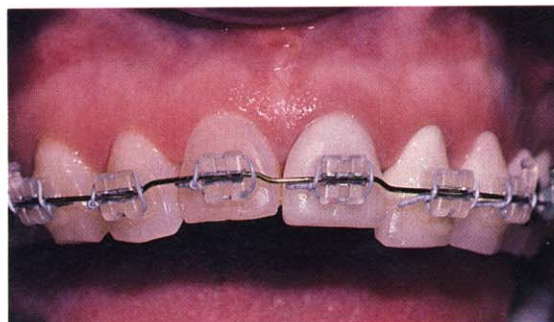

Figure 3C—Gingival levels were aligned instead of the incisal edges. The left lateral incisor was extruded and equilibrated, and the central incisors were intruded.

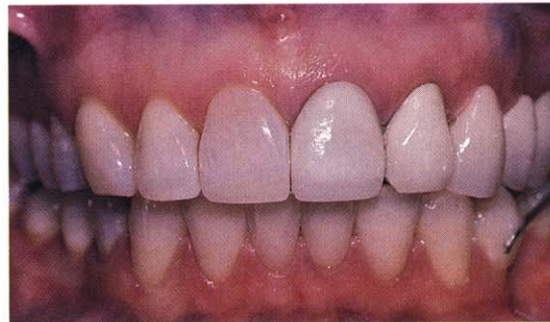


Figure 3D—The incisal edge discrepancies were temporarily restored with composite until more permanent restorations could be completed.

tal surgery.^{4,5}

In this case, the combined orthodontic-restorative solution was adopted. Orthodontic brackets were placed near the incisal edges of the maxillary central incisors and in the mid-

dle of the crown on the maxillary canines (Figure 2B). The posterior teeth were used as anchorage to facilitate an intrusive force on the maxillary central incisors. The gingival margins of the maxillary canines were used as a

guide for intruding the maxillary central incisors. When the proper vertical position of the central incisors was achieved, the patient had an open bite between the maxillary and mandibular incisors (Figure 2B). This discrepancy was eliminated by placing porcelain crowns on the central and lateral incisors to restore crown length and establish proper incisal edge position (Figure 2C).

Figure 4A—The incisal edges of this patient's maxillary incisors were chemically eroded as a result of bulimia.

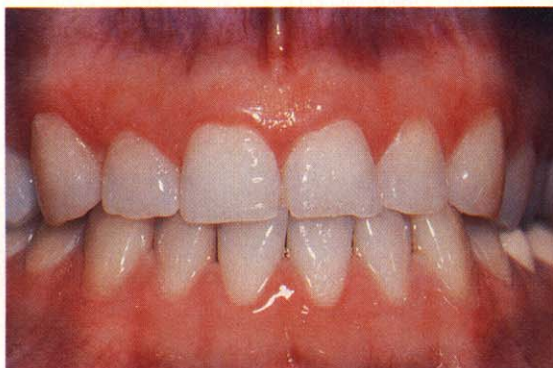

Figure 4B—Lingual erosion of the incisors extended into the dentin.

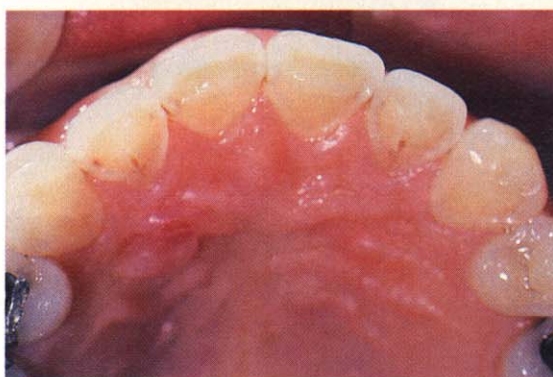

Figure 4C—To recreate proper crown length and establish lingual restorative space for crowns, the maxillary incisors were intruded using the gingival margins of the canines as a guide.

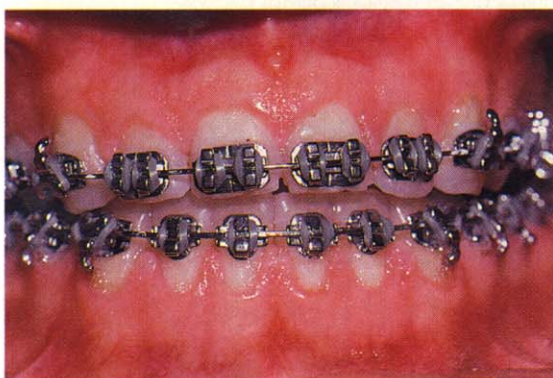
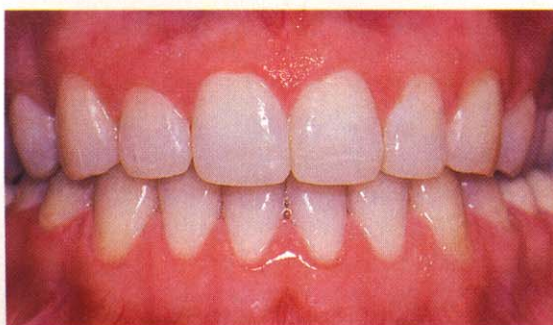
Figure 4D—After the orthodontic intrusion, the incisal edges were temporarily restored with composite until more permanent restorations could be constructed.



A common concern about this amount of tooth intrusion is the possibility of root resorption at the apexes of the maxillary central incisors resulting from the intrusive force. Investigations have shown that heavy intrusive forces can produce root resorption in monkeys.⁶ Nevertheless, root resorption is not a problem in the type of case described here because the light nickel titanium wires used in the gingival leveling process do not create excessive force on the roots; therefore, they do not produce root resorption. The orthodontic intrusion achieved in this case provided the space needed to lengthen the incisal edges of the patient's maxillary incisors, and moved the gingival margins apically, thereby eliminating the "gummy smile" (Figure 2D).

Case 3

This 29-year-old woman was missing her maxillary left canine and first premolar. The teeth had been replaced 10 years earlier with a fixed bridge that extended from the maxillary left lateral incisor to the second premolar. The bridge was scheduled to be redone. In addition, the patient was unhappy with the uneven gingival levels between her central and lateral incisors and the fact that her maxillary left lateral incisor was longer than the central incisors (Figure 3A). How could this crown-length dilemma be solved before reconstruction of the anterior bridge?

One option was periodontal surgery to cover the longer porcelain crown on the left lateral incisor. The chance of predictably covering the labial surface of the lateral incisor would not be good, however, because the crown was porcelain rather than enamel. Another option (the one used in this case) was to orthodontically extrude the left lateral incisor and simultaneously intrude the central incisors.⁷ The right central incisor was shorter than the right lateral incisor, and the left central incisor was scheduled to be restored at the same time as the bridge.

To implement this treatment plan, the orthodontic brackets were placed incisally on the central incisors and gingivally on the lateral incisors (Figure 3B). As the left lateral incisor erupted, the incisal edge was equilibrated to avoid an occlusal prematurity. During the extrusive-intrusive process, the central incisor gingival margins moved apically into a better esthetic relationship with the laterals and

canines (Figure 3C).

At the conclusion of the orthodontic treatment, the incisal edges were temporarily restored with composite bonding (Figure 3D). After the teeth stabilized, more permanent restorations with crowns and veneers were done.

Allowing sufficient time for stabilization of the orthodontically treated teeth is important, because the teeth may relapse into their former positions. An intruded tooth can re-erupt if the teeth are not stabilized. Studies on

laboratory animals have shown that during the intrusive or extrusive process, the principal fibers of the periodontium become stretched and oriented in a more oblique fashion.⁸ Over time, however, these fibers reorient themselves and accommodate to the new vertical position of the extruded or intruded tooth. In laboratory animals, this process may take only 1 month. In the author's experience, the stabilization process takes at least 6 months in patients. Therefore, after the intrusion or extrusion process has been accomplished, the teeth must be stabilized by retaining the orthodontic brackets for an additional 6 months, or by splinting the affected tooth to the adjacent teeth.

Case 4

This 32-year-old woman had bulimia, and stomach acid had eroded the incisal edges of her maxillary incisors and destroyed the lingual enamel surfaces of the maxillary central and lateral incisors (Figures 4A and 4B). In occlusion, the exposed dentin surfaces of the centrals and laterals were in contact with the mandibular incisors. The patient was scheduled to have crowns placed on her maxillary central and lateral incisors. However, two problems needed to be solved first. First, the maxillary incisors had overerupted because of the lingual erosion, and the shape of the central incisors was square. Second, because of the lingual wear, the restorative dentist was reluctant to reduce the lingual surfaces of these teeth further during the preparation for porcelain crowns. Additional lingual reduction could result in pulp exposure.

The solution to both problems was an interdisciplinary treatment plan of orthodontics and restorative dentistry. The first step was to intrude the maxillary central and lateral incisors.⁹ This would relocate the labial gingival margins to their former level, create incisal space for longer incisal crowns, and create lingual space to avoid further lingual tooth reduction. The gingival margin heights of the canines were used to guide the proper vertical position of the central incisors. The gingival levels of the lateral incisors were positioned slightly coronal to those of the centrals and canines (Figure 4C).

During the finishing stage of orthodontic treatment, the incisal and lingual surfaces of the maxillary centrals and laterals were restored

Figure 5A—This patient was unhappy with her short maxillary incisors. The incisors were abraded because she had an end-to-end occlusion of the maxillary and mandibular incisors.

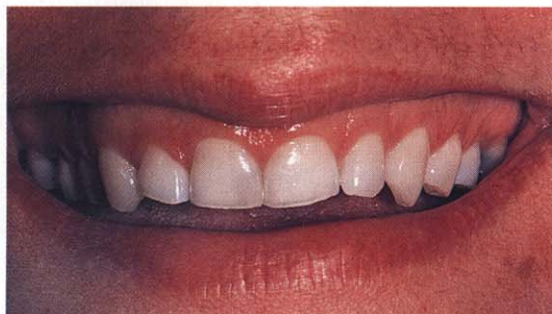

Figure 5B—The gingival margins were already in proper relationship, so the orthodontic treatment simply required retraction of the mandibular incisors to establish restorative space.

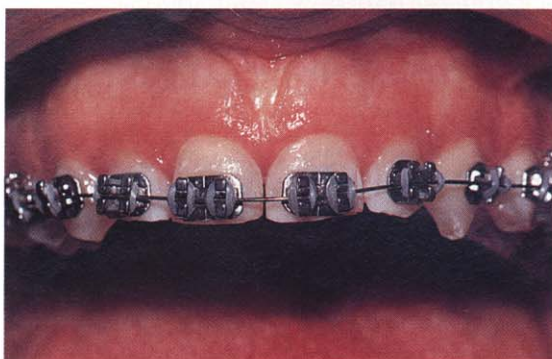

Figure 5C—After the orthodontic treatment, the restorative dentist could reconstruct crowns of greater length with more ideal width-to-length ratios.

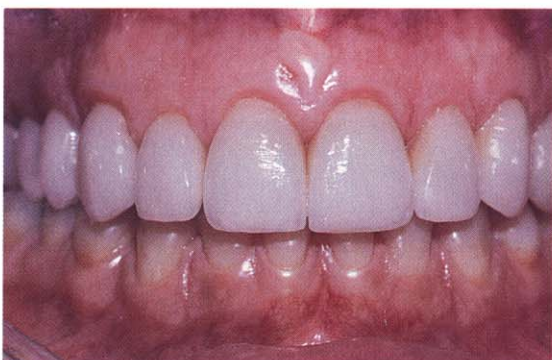
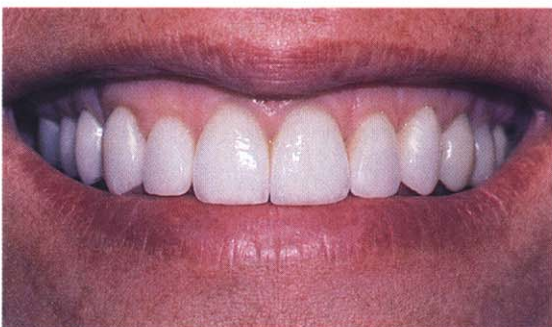
Figure 5D—The esthetics of the patient's smile were greatly improved with combined orthodontics and restorative dentistry.



temporarily with composite to create proper crown length and thickness (Figure 4D). This method of intrusion and restoration was an effective way to treat the bulimic patient with significant chemical abrasion of the incisal and lingual surfaces of the anterior teeth.

Case 5

This 38-year-old woman was concerned about her short, unesthetic maxillary incisors (Figure 5A). She did not have a protrusive bruxing habit, but she did have an end-to-end relationship of the maxillary and mandibular incisors in centric occlusion. As a result, her incisal edges had become worn simply from normal function over several years. The patient wanted longer incisors.

It would be nearly impossible to resolve this patient's problems without combined orthodontics and restorative dentistry. To create restorative space, the mandibular incisors were retracted lingually. In this patient, the maxillary central incisors did not require intrusion. The gingival levels of the centrals, laterals, and canines were already positioned ideally. Unlike Case 4, the central incisors had not overerupted as a result of incisal wear during the years of abrasion. The goal of orthodontic treatment for this patient was not to change the gingival levels, but to simply retract the mandibular incisors to provide restorative space (Figure 5B).

Comparison of the pre- and posttreatment intraoral and smiling photographs show that the gingival levels were maintained. The restorative dentist was able to lengthen the incisal edges of the maxillary incisors as the mandibular anterior teeth were retracted (Figures 5C and 5D).

Summary

This article illustrates the benefits of combined orthodontic and restorative management of patients with vertical discrepancies in the position of the maxillary incisors. When maxillary teeth abrade as a result of trauma, bruxism, or supereruption, they create a significant challenge for the restorative dentist. By recognizing inadequacies in crown length and gingival margin levels before restorative intervention, the restorative dentist can take advantage of the benefits of orthodontic vertical repositioning of the incisors to enhance the esthetic and functional results.

References

1. Kokich V, Nappen D, Shapiro P: Gingival contour and clinical crown length: their effects on the esthetic appearance of maxillary anterior teeth. *Am J Orthod* 86:89-94, 1984.
2. Kokich V: Enhancing restorative, esthetic, and periodontal results with orthodontic therapy. In Schluger S, Yuodelis R, Page R, et al (eds): *Periodontal Therapy*. Philadelphia, Lea and Feiberger, pp 433-460, 1990.
3. Kokich V: Anterior dental esthetics: an orthodontic perspective. Part 1. Crown length. *J Esthet Dent* 5:19-23, 1993.
4. Kokich V: Anterior dental esthetics: an orthodontic perspective. Part 2. Vertical relationships. *J Esthet Dent* 5:174-178, 1993.
5. Chiche G, Kokich V, Caudill R: Diagnosis and treatment planning of esthetic problems. In Pinault A, Chiche G (eds): *Esthetics in Fixed Prosthodontics*. Chicago, Quintessence Publishing Co Inc, pp 33-52, 1994.
6. Dellinger E: A histologic and cephalometric investigation of premolar intrusion in the *Macaca speciosa* monkey. *Am J Orthod* 53:325-355, 1967.
7. Kokich V: Esthetics: the ortho-perio-restorative connection. *Sem Orthod Dentofac Orthop* 2:21-30, 1996.
8. Reitan K: Tissue rearrangement during retention of orthodontically rotated teeth. *Angle Orthod* 29:105-113, 1959.
9. Kokich V, Spear F: Guidelines for treating the orthodontic-restorative patient. *Sem Orthod Dentofac Orthop* 3:3-20, 1997.