



Open gingival embrasures after orthodontic treatment in adults: Prevalence and etiology

Jacklyn R. Kurth, DDS, MSD,^a and Vincent G. Kokich, DDS, MSD^b

Auburn and Tacoma, Wash

The purposes of this study were to determine the prevalence of posttreatment open gingival embrasures in adult orthodontic patients and to examine the association of pretreatment maxillary incisor malalignment, posttreatment alveolar bone height, interproximal contact position, root angulation, crown shape, and embrasure area with open gingival embrasures. Posttreatment intraoral photographs of 337 adult orthodontic patients were evaluated to determine the prevalence of open gingival embrasures. A subsample of 119 patients was identified for measurement and divided into 2 groups: normal gingival embrasures and open gingival embrasures. Digital images of the pretreatment maxillary models and posttreatment maxillary central incisor periapical radiographs were made to measure the pretreatment and posttreatment variables. The prevalence of posttreatment open gingival embrasures in adult orthodontic patients was 38%. Pretreatment maxillary central incisor rotation and overlap were not statistically associated with posttreatment open gingival embrasures. A posttreatment alveolar bone–interproximal contact distance greater than 5.5 mm was associated with open gingival embrasures. Short and more incisally positioned posttreatment interproximal contacts were associated with open gingival embrasures. Open gingival embrasures were found to have more divergent root angulations and more divergent or triangular-shaped crown forms than normal gingival embrasures. Embrasure areas larger than 5.09 mm² were also correlated with open gingival embrasures. Increased alveolar bone–interproximal contact distance and increased root angulation demonstrated the greatest increase in the odds of an association with an open gingival embrasure. This investigation indicates that open gingival embrasures are common in adults who have undergone orthodontic treatment and that posttreatment variables are significant factors in open gingival embrasures. (*Am J Orthod Dentofacial Orthop* 2001;120:116-23)

The number of adults seeking orthodontic therapy is increasing. In recent years, it has been estimated that up to 40% of all orthodontic patients are adults.^{1,2} Adult patients present a challenge to orthodontists because they have high esthetic demands and they often have dental conditions that may complicate treatment, such as tooth wear, poorly contoured restorations, and periodontal disease. In some adults, a black triangular space may appear between the maxillary central incisors and the cervical gingival margin after orthodontic treatment. This open gingival embrasure may appear unesthetic, and it may affect the periodontium by causing chronic food retention. One study

showed that open gingival embrasures occurred in 41.9% of adolescent patients treated for crowding of maxillary central incisors.³ However, the prevalence and the etiology of open gingival embrasures in adult orthodontic patients are unknown.

Several underlying causes of open gingival embrasures after orthodontic treatment have been suggested. Severely malaligned maxillary incisors are often associated with posttreatment open gingival embrasures. Atherton⁴ described dimensional changes in the interdental papilla during alignment of maxillary central incisors as a stretching and blunting of the papilla. The height of the alveolar bone relative to the interproximal contact is a significant factor in determining whether a papilla will fill the gingival embrasure.⁵ The location and the size of the interproximal contact and divergent root angulation have been cited as potential causes of open gingival embrasures.⁶ Triangular-shaped crown form also may be associated with open gingival embrasures. However, no study has evaluated open gingival embrasures from a multifactorial viewpoint.

Examining the factors associated with open gingival embrasures may enable the orthodontist to prevent

^aIn private practice.

^bProfessor, Department of Orthodontics, School of Dentistry, University of Washington.

Reprint requests to: Jacklyn R. Kurth, DDS, MSD, 1268 East Main St, Auburn, WA 98002-5798; e-mail, jrKurth@juno.com.

Submitted, February 2000; revised and accepted, December 2000.

Copyright © 2001 by the American Association of Orthodontists.

0889-5406/2001/\$35.00 + 0 8/1/114831

doi:10.1067/mod.2001.114831

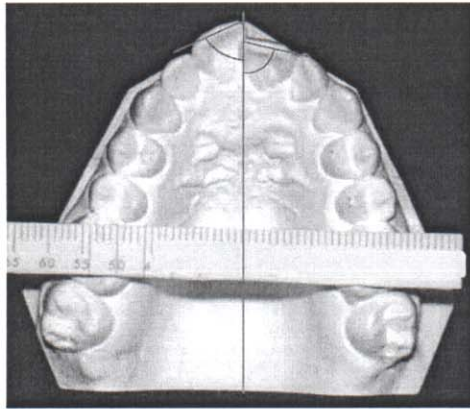


Fig 1. Maxillary central incisor rotation.

or eliminate this unesthetic problem during the finishing stages of orthodontic treatment. Therefore, the purposes of this study were (1) to determine the prevalence of posttreatment open gingival embrasures in adults who have undergone orthodontic treatment and (2) to examine the association of pretreatment maxillary incisor malalignment, posttreatment alveolar bone height, interproximal contact position, root angulation, crown shape, and embrasure area with open gingival embrasures.

MATERIAL AND METHODS

About 4500 patient records from 2 private orthodontic offices were reviewed. Patients were selected on the basis of the following criteria: (1) they were at least 20 years old at the start of orthodontic treatment; (2) treatment included fixed appliance therapy in the maxilla; (3) treatment was completed by 1988; (4) there were no restorations or alterations of the mesial surfaces of the maxillary central incisors; and (5) posttreatment frontal intraoral photographs were available. Thus, a sample of 337 subjects was obtained and used to determine the prevalence of open gingival embrasures between maxillary central incisors in adult patients after orthodontic treatment.

In determining the prevalence, each frontal intraoral slide was projected onto a screen for classification into 1 of 5 categories: a normal gingival embrasure, a mild open gingival embrasure, a moderate open gingival embrasure, a severe open gingival embrasure, or a diastema. The *gingival embrasure* was defined as the embrasure located cervical to the interproximal contact, and it was considered open if the embrasure space was not completely occupied by gingiva. The raters

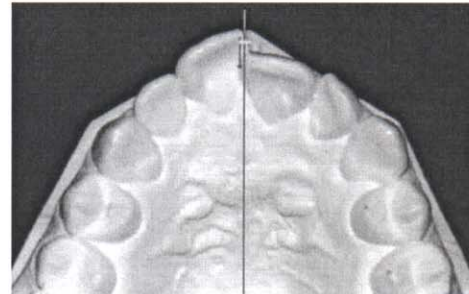


Fig 2. Maxillary central incisor overlap.

evaluated the patients independently and were instructed to use their clinical judgment to categorize them. Twenty randomly selected slides were evaluated a second time 4 months later to determine the raters' reliability.

Once the slides had been classified, a subsample of 140 patients with posttreatment maxillary central incisor periapical radiographs was selected. The subsample consisted of 97 women (69%) and 43 men (31%) ranging in age from 20 to 77 years, with a mean age of 31 years 9 months. Measurements of pretreatment maxillary central incisor overlap and rotation, and posttreatment alveolar bone height, interproximal contact height, crown shape, root angulation, and embrasure area were made on this subsample to determine whether there is an association between these factors and open gingival embrasures.

Pretreatment variables

Pretreatment maxillary incisor overlap and rotation were assessed to test the theory that increased overlap or rotation results in posttreatment open gingival embrasures. Occlusal digital images of the pretreatment maxillary models were made. The images were then imported for calibration and analysis into the public domain NIH Image program (developed at the US National Institutes of Health and available on the Internet at <http://rsb.info.nih.gov/nih-image/>). Maxillary central incisor rotation was measured as the angle formed by the incisal edge and the midpalatal raphe (Fig 1). Maxillary central incisor overlap was measured by the distance between the mesial contacts of the central incisors perpendicular to the midpalatal raphe (Fig 2). If there was normal contact of the incisors, the value was zero. If there was overlap, the measured value would be positive. In the case of a diastema, the distance between the central incisors would be a negative value.

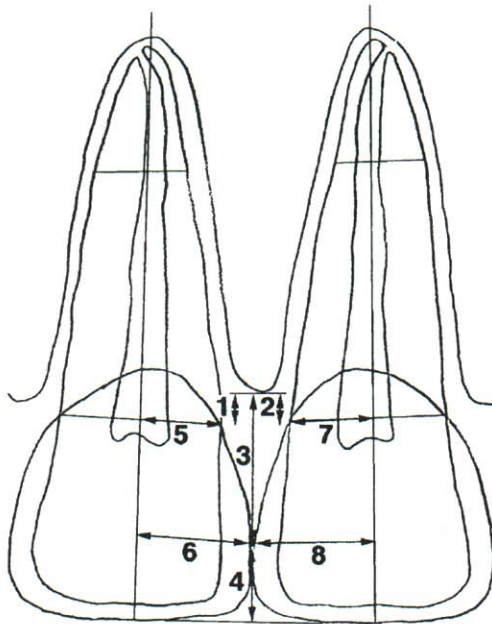


Fig 3. Posttreatment linear variables: 1, right alveolar bone-CEJ; 2, left alveolar bone-CEJ; 3, alveolar bone-interproximal contact; 4, interproximal contact-incisal edge; 5, right axis-CEJ; 6, right axis-interproximal contact; 7, left axis-CEJ; 8, left axis-interproximal contact.

Posttreatment variables

All posttreatment variables were assessed from the maxillary central incisor periapical radiographs. A digital image of each periapical radiograph was made, and several points and lines were identified to measure the posttreatment variables, including the height of the alveolar crest, the mesial cemento-enamel junction (CEJ), the interproximal contact, the incisal edge, and the long axis of the tooth.

Alveolar bone height is associated with open gingival embrasures.⁵ Interproximal contact position may also influence open gingival embrasure formation.^{5,6} The distances from the alveolar bone to the CEJ and from the alveolar bone to the interproximal contact were expected to be greater in patients with posttreatment open gingival embrasures. The distance from the CEJ to the alveolar bone was measured parallel to the long axis of the tooth (Fig 3). The interproximal contact was marked at the most gingival point, where the mesial surfaces of the central incisor crowns were in contact, or at the most gingival point where the space between the mesial surfaces of the central incisor

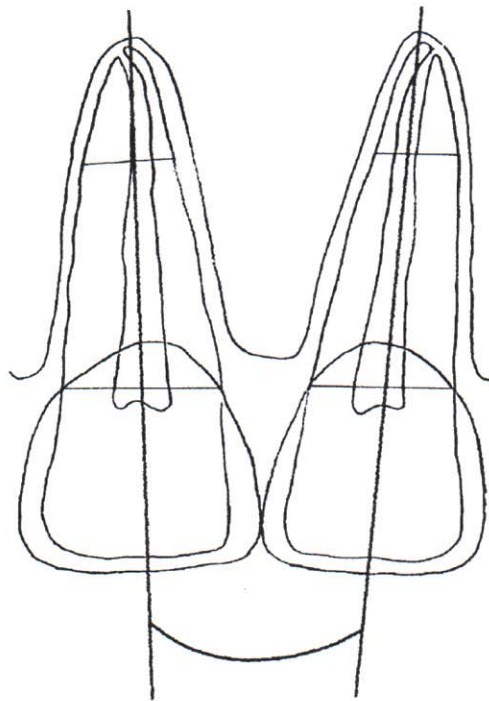


Fig 4. Posttreatment root angulation.

crowns was the narrowest. The distance from the alveolar bone to the interproximal contact was measured perpendicular to the alveolar crest (Fig 3). The distance from the interproximal contact to the incisal edge was also measured to test the hypothesis that interproximal contacts closer to the incisal edge are associated with open gingival embrasures (Fig 3).

An association between triangular or divergent crown forms and the appearance of posttreatment open gingival embrasures has been postulated.⁶ A ratio representing the divergence of the mesial aspect of the central incisor crowns was calculated to investigate this hypothesis by comparing the perpendicular distance from the mesial CEJ and the mesial contact to the long axis of the tooth (Fig 3). A low mesial divergence ratio represents a more divergent or triangular crown form, whereas a ratio near 1 represents a less divergent or rectangular crown form.

Excessive distal root angulation of the maxillary central incisors is thought to be associated with posttreatment open gingival embrasures.⁶ The angle between the 2 central incisor long axes was measured to evaluate this assumption (Fig 4). Parallel roots were assigned a zero

angular value. If the vertex of the angle was located apically, the roots were considered convergent, and a negative angular value was recorded. If the vertex of the angle was located incisally, the roots were considered divergent, and a positive angular value was recorded.

Embrasure area was also measured, since a large area may be associated with posttreatment open gingival embrasures. The perimeter of this triangular space included a line tangent to the height of the interproximal alveolar crest and the mesial portions of the right and left central incisor roots and crowns (Fig 5). This outlines the space that the papilla should occupy.

One examiner recorded all measurements. Complete pretreatment and posttreatment measurements were repeated for 10 randomly selected patients to determine the examiner's reliability.

Data analysis

The agreement and reproducibility among raters was determined by using a kappa statistic. After 3 categories—normal gingival embrasure, open gingival embrasure, and diastema—had been reliably established, the prevalence of open gingival embrasures in the patient sample was calculated. The subsample of patients with open or normal gingival embrasures was identified, and the pretreatment and posttreatment measurements were performed. The mean for each group was calculated and compared by using a *t* test ($P < .05$). An odds ratio was calculated to interpret the mesial crown-form variables. Measurements performed on the subsample were examined for reliability by using intraclass correlation coefficients on repeated measurements. Logistic regression analysis was used to identify associations among multiple variables.

RESULTS

During the independent classification of 337 frontal intraoral slides, the raters did not agree on the severity of open gingival embrasures. Therefore, the original 5 categories were collapsed into normal gingival embrasure, open gingival embrasure, and diastema. With these categories, 91% of the time at least 4 of 5 patient ratings were the same, demonstrating high agreement among raters (Table I). The overall kappa statistic was .75, indicating good agreement ($P < .001$).

The number of ratings in each category determined the classification of each patient. If all 5 raters or 4 out of 5 raters agreed on the classification, the patient was placed in this category. Nine percent of the time only 2 or 3 raters agreed that an open gingival embrasure was present. Because of the considerable disagreement in classifying those patients, they were placed into a category called indistinguishable.

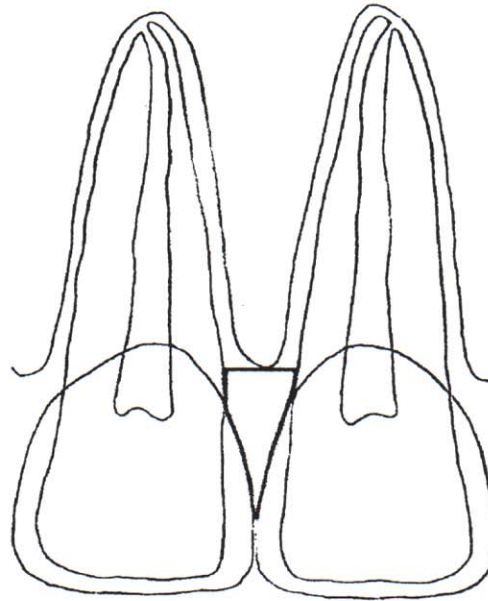


Fig 5. Posttreatment embrasure area.

Twenty slide classifications were compared from 2 rating periods by a kappa statistic to assess intrarater reliability. The kappa statistic was high, .84 ($P < .001$), indicating substantial agreement.

Reliability of the examiner and the imaging technique was assessed by computing intraclass correlation coefficients for the repeated measurements. These coefficients ranged from .78 to .99 ($P < .0014$ to .0001); this indicates high reliability of the measurements.

Patients were ultimately categorized into 1 of 4 categories: normal gingival embrasure, open gingival embrasure, diastema, and indistinguishable. In this sample, 50% had normal gingival embrasures, 38% had open gingival embrasures, 5% had diastema, and 7% were indistinguishable. The subsample reflected nearly the same prevalence (Table II). For patients with periapical radiographs, further measurements were made only on those who fell within the groups clearly categorized as normal gingival embrasure and open gingival embrasure to provide a sample of 119 patients.

Pretreatment variables

Incisor rotation was assessed by taking the absolute value of the measured angle centered at 90°. This measurement quantifies the severity of obtuse or acute incisor rotation angles. The group with open gingival

Table I. Individual rater classification results

	Rater 1	Rater 2	Rater 3	Rater 4	Rater 5
Normal embrasure	167 (50%)	187 (55%)	182 (54%)	171 (51%)	160 (47%)
Open embrasure	155 (46%)	129 (38%)	137 (41%)	147 (44%)	161 (48%)
Diastema	15 (4%)	22 (7%)	18 (5%)	19 (6%)	16 (5%)
Total	337 (100%)	337 (100%)	337 (100%)	337 (100%)	337 (100%)

Table II. Prevalence of open gingival embrasure

	Sample	Subsample
Normal embrasure	168 (50%)	71 (51%)
Open embrasure	128 (38%)	48 (34%)
Diastema	17 (5%)	6 (4%)
Indistinguishable	24 (7%)	15 (11%)
Total	337 (100%)	140 (100%)

embrasures had slightly greater incisor rotation than the normal gingival embrasure group, but this was not statistically significant (Table III). Of all rotations observed, 87% were distal rotations; only 13% of the central incisors were rotated mesially.

Incisor overlap was evaluated in both linear and categorical manners. The linear measurements showed that both groups had a negative mean value (Table III). This was not a statistically significant difference but, strangely, indicated a slight tendency for patients with normal gingival embrasures to have larger diastemas before treatment than the open gingival embrasure group. The most likely cause of the negative mean values are the anatomical constraints placed on the amount of overlap, such as tooth shape and faciolingual alveolar bone width, which do not influence diastema size. The maximum overlap of 1.81 mm and maximum diastema of -4.72 mm reflect this discrepancy.

Assuming that a large negative value (diastema) had the same clinical relevance as a smaller positive value (overlap), the influence of magnitude on our scaled values was removed. Patients were assigned to 1 of 3 categories: overlap (positive value), diastema (negative value), or normal contact (zero value). However, the differences between categories, as shown in Table IV, were not statistically significant at $P = .05$.

Posttreatment variables

Left and right measurements of alveolar bone height to the CEJ were highly correlated ($r^2 = 0.95$). Thus, posttreatment alveolar bone height was computed by taking the average of left and right measurements. Patients with open gingival embrasures had a slightly larger average distance from the crest of alveolar bone to the CEJ, but this difference was not statistically significant (Table III).

Statistically significant differences were found between the 2 groups for the remaining posttreatment variables (Table III). The mean distance from alveolar bone to the interproximal contact was markedly greater for patients with open gingival embrasures (7.01 mm) than for patients with normal gingival embrasures (5.5 mm). The interproximal contact was closer to the incisal edge, and the contact height was nearly 1 mm smaller in patients with open gingival embrasures. The embrasure area was 3.07 mm² larger in patients with detectable open gingival embrasures than in patients with normal gingival embrasures. The mean root angulation for the normal gingival embrasures group had a negative value, indicating the average root angulation was convergent. The mean root angulation for the open gingival embrasure group had a zero value, indicating parallel roots. Patients with open gingival embrasures had more root divergence than those with normal gingival embrasures.

A comparison of the mesial crown form ratio for patients with open gingival embrasures and patients with normal gingival embrasures suggests a slightly more divergent or triangular tooth shape for patients with open gingival embrasures (Table III). The odds ratio provides a more clinically applicable interpretation of this result (Table V). It was found that for every 1 mm increase in distance from the mesial contact to the root axis, the odds of observing an open gingival embrasure increase by 6.

Logistic regression

Neither of the pretreatment variables was significant in changing the odds of producing an open gingival embrasure. Models including posttreatment variables demonstrated that root angulation, alveolar bone-interproximal contact distance, and crown form caused a statistically significant increase in odds of an open gingival embrasure. In these models, the standard error and P values were inflated because of the correlation of some variables, particularly those with shared landmarks.

DISCUSSION

The results of this study show that an open gingival embrasure is a common posttreatment finding in adult orthodontic patients. In this sample, 38% of adults had

Table III. Posttreatment measurements

	Normal embrasure mean (SE)	Open embrasure mean (SE)	Difference mean (SE)	P value
Maximum rotation (degrees)	17.5 (1.3)	20.3 (1.6)	2.8 (2.1)	.176
Left incisor rotation (degrees)	14.6 (1.2)	17.0 (1.7)	2.4 (2.0)	.254
Right incisor rotation (degrees)	12.9 (1.2)	14.6 (1.4)	1.7 (1.8)	.365
Overlap (mm)	-0.33 (0.14)	-0.15 (0.14)	0.18	.389
Alveolar bone to CEJ (mm)	1.95 (0.14)	2.28 (0.15)	0.33 (0.21)	.112
Alveolar bone to interproximal contact (mm)	5.50 (0.18)	7.01 (0.18)	1.51 (0.27)*	< .0001
Interproximal contact to incisal edge (mm)	4.58 (0.14)	3.61 (0.20)	-0.97 (0.24)*	.0001
Maxillary central incisor root angulation (degrees)	-3.65 (0.58)	0.00 (0.71)	3.65 (0.91)*	.0001
Maxillary central incisor crown form	0.80 (0.01)	0.78 (0.01)	-0.02 (0.01)†	.018
Embrasure area (mm ²)	5.09 (0.28)	8.16 (0.45)	3.07 (0.50)*	< .0001

* $P < .0001$; † $P = .02$.

an open gingival embrasure between the maxillary central incisors after orthodontic treatment. Burke³ found a 42% prevalence of open gingival embrasures in adolescent orthodontic patients with crowded maxillary central incisors. Burke extrapolated that only 15% of the general adolescent orthodontic population should have an open gingival embrasure. He assumed that only patients with crowded maxillary central incisors are susceptible to the formation of open gingival embrasures. However, pretreatment maxillary central incisor crowding was not statistically associated with open gingival embrasures in our study. Therefore, it is suspected that the prevalence of open gingival embrasures in adults and adolescents may be similar. Specific factors known to cause open gingival embrasures—such as periodontal disease, periodontal surgery,⁷ and orthognathic surgery^{8,9}—are more common in adult patients and may cause a slightly greater prevalence of open gingival embrasures in adults than in adolescents. Further investigation of an adolescent sample would be required to provide a definitive comparison. Regardless of its etiology, orthodontists should be aware that open gingival embrasures after orthodontic treatment occur in more than one third of adult patients and therefore should be discussed with them before treatment begins. To effectively eliminate this unesthetic space, practitioners must determine which factors are contributing to the open embrasure and modify them accordingly.

Increased distance from the crest of the alveolar bone to the interproximal contact was significantly related to open gingival embrasures. Logistic regression analysis of multiple variables indicated that if crown form, root angulation, and contact-incisal edge distance were held constant, a 1-mm increase in bone-contact height increases the odds of an open gingival embrasure by 78% to 97%. These statistically significant results confirm the trends found by Tarnow et al.⁵ Through clinical bone sounding, Tarnow's group demonstrated

Table IV. Presence of pretreatment maxillary central incisor overlap

	Normal embrasure	Open embrasure
Overlap	24% (17)	42% (20)
Zero overlap	54% (38)	42% (20)
Diastema	22% (16)	16% (8)
Total	100% (71)	100% (48)

Table V. Maxillary central incisor mesial crown form odds ratio

	Odds ratio	Standard error	P value	95% Confidence interval
Axis-CEJ	0.17	0.13	.022	0.03-0.77
Axis-contact	6.01	4.72	.022	1.29-28.00

that a patient with a crest of bone-interproximal contact distance of 5 mm had an open gingival embrasure only 2% of the time. A crest of bone-contact distance of 6 mm produced an open gingival embrasure 44% of the time, and a crest of bone-contact distance of 7 mm had an open gingival embrasure 73% of the time. These findings indicate that the papilla will extend only a limited distance from the alveolar crest to the interproximal contact. Since the mean distance from alveolar bone to CEJ was constant throughout our sample, the variation in the alveolar bone-contact measurement is most likely due to the position of the contact. Therefore, in patients with open gingival embrasures, practitioners should evaluate the distance between alveolar bone and interproximal contact and decide whether moving the contact gingivally is a reasonable solution. The contact position can be changed by removing interproximal enamel, adding a restoration, or altering root angulation. The distance from alveolar bone to interproximal contact is a contributing factor in open gingival embrasures,

and the position of the contact may be the source of the problem.

The mean distance from the crest of the alveolus to the CEJ was not statistically different in this investigation. The average distance from alveolar bone to CEJ in patients with normal and open gingival embrasures was 1.95 mm and 2.28 mm, respectively. Actually, the mean distances for both groups would be considered within normal limits for a periodontally healthy adult. This does not conflict with Tarnow's findings; it merely indicates that few periodontal patients were involved in our sample. To better assess the relationship between bone level and open gingival embrasures, a sample of more periodontal patients would be required.

The length of the interproximal contact is another variable that may produce open gingival embrasures. On average, the interproximal contact, in patients with open gingival embrasures, was shorter or located 1 mm more incisally than in patients with normal gingival embrasures. Since the incisal edge is a fixed reference point, the mean difference in contact position is probably due to a difference in length of the interproximal contact. When evaluated simultaneously with other variables, the length of the interproximal contact did not significantly affect the odds of producing an open gingival embrasure. In an ideal esthetic situation, the interproximal contact should be about halfway between the cervical gingival margin and the incisal edge of maxillary central incisors.⁶ Although contact position was not measured from the cervical gingival margin in this study, the results suggest that the interproximal contact is about halfway between the alveolar bone and the incisal edge in patients with normal gingival embrasures. When one is planning to correct an open gingival embrasure, the interproximal contact location should be considered in conjunction with crown form and root angulation.

These data show that root angulation of the maxillary central incisors is related to open gingival embrasures. Mean root angulation in normal gingival embrasures converges at 3.65°. When mesial crown form, alveolar bone–interproximal contact, and interproximal contact–incisal edge variables are constant, a 1° increase in root divergence increased the odds of an open gingival embrasure by 14% to 21%. These results agree with other authors' statements about the correlation between root angulation and open gingival embrasures.^{3,6} Orthodontic bracket placement should be determined by root position and not by the existing incisal edge to avoid aberrant root angulation. In many adult malocclusions, the incisal edges are abraded and, if undetected, will result in improper bracket placement. Orthodontists should assess periapical radiographs of patients with open gingival embrasures to determine

whether altering root angulation is the appropriate treatment. This investigation has shown that root angulation is strongly associated with open gingival embrasures in adult orthodontic patients.

This study indicates that the mesial crown form of maxillary central incisors is significantly related to open gingival embrasures. The lower mean crown form ratio in patients with open gingival embrasures suggests a slightly more divergent crown form in these subjects. Evaluating the 2 components of the crown form ratio simultaneously showed that for each millimeter increase from the mesial contact to the long axis, the odds of an open gingival embrasure increased 6 times. Adding root angulation to this regression model increases these odds 13 times. However, when the alveolar bone–contact variable was added to this model, the crown form became much less significant, and its effect was decreased. Divergent crown form has been cited as a contributing factor to open gingival embrasures.^{3,6} While examining the range of variation and the frequency of incisor crown forms, Taylor detected 3 basic types and listed them in decreasing frequency: square, tapered, and ovoid.¹⁰ Clinicians should expect a moderate number of adult patients to have tapered crowns, making them more susceptible to open gingival embrasures. Accurate diagnosis of tapered crown form is essential so that the appropriate interproximal contact stripping or restorative procedures may be performed. Crown form is clearly a common source of open gingival embrasures in orthodontic patients.

This investigation could not demonstrate any statistically significant difference in pretreatment maxillary central incisor rotation or overlap between patients with normal or open gingival embrasures. Logistic regression revealed that neither rotation nor overlap had a significant impact on the odds of developing an open gingival embrasure. These results contradict the general perception that pretreatment maxillary incisor overlap predisposes a patient to posttreatment open gingival embrasures. They also challenge the theory that a short papilla in an overlapped incisal area will not fill a normal-sized embrasure after the teeth are aligned. However, Burke may be correct in stating that a "black triangle" is a frequent sequela of aligning crowded maxillary central incisors.³ When central incisors are overlapped, the incisal edges will wear unevenly. Since the incisal edge is a primary reference for bracket placement, undetected incisal wear may lead to incorrect bracket placement. This bracket position may align the incisal edges but could also produce divergent root alignment and an open gingival embrasure. Malaligned incisors may also have excessive root

tipping. If this tipping is not accurately detected during bracket placement or corrected during orthodontic finishing, an open gingival embrasure may appear. These compounding effects of incisor malalignment may explain why preorthodontic incisor overlap and rotation did not result in posttreatment open gingival embrasures.

The size of the gingival embrasure area is a significant determinant of open gingival embrasures. Patients with open gingival embrasures had significantly larger mean embrasure areas than did patients with normal gingival embrasures. Although no researchers have tried to measure the embrasure area, other investigators have reported mean data for different components of this triangular embrasure space. After evaluating intraoral photographs and models, Burke et al³ reported a mean width of the triangle base of .43 mm. Bone sounding by Tarnow et al⁵ showed that the vertical height from bone to contact ranged between 6 and 10 mm. Using the embrasure area as a clinical tool is limited, because it is difficult to calculate without digitizing the periapical radiograph with use of a computer. A 3-dimensional analysis of the interproximal area would provide further insight on the gingival response to interdental dimensional changes.

CONCLUSIONS

The purpose of this study was to investigate the prevalence of open gingival embrasures and to examine specific factors associated with them in adult orthodontic patients. Accurate assessment of these factors will enable practitioners to choose the appropriate treatment to eliminate open gingival embrasures and enhance the esthetic outcome of orthodontic therapy. The results of this study indicate the following:

1. The prevalence of posttreatment open gingival embrasures in an average adult orthodontic population is about 38%.
2. Pretreatment maxillary central incisor rotation and overlap are not directly associated with posttreatment open gingival embrasures.
3. An increased distance from the alveolar bone to the interproximal contact is correlated with open gingival embrasures after orthodontic therapy.
4. Shorter and more incisally positioned interproximal contacts are associated with posttreatment open gingival embrasures.
5. Posttreatment maxillary central incisor root angulation is slightly convergent in normal gingival embrasures.
6. Divergent or triangular-shaped crown forms are associated with posttreatment open gingival embrasures.
7. Increased embrasure area is associated with open gingival embrasure formation.

REFERENCES

1. Kokich VG, Mathews DP. Managing treatment for the orthodontic patient with periodontal problems. *Semin Orthod* 1997;3: 21-38.
2. LaSota EP. Orthodontic considerations in prosthetic and restorative dentistry. *Dent Clin North Am* 1988;32:447-56.
3. Burke S, Dent IV, Burch JG, Tetz JA. Incidence and size of pretreatment overlap and posttreatment gingival embrasure space between maxillary central incisors. *Am J Orthod Dentofacial Orthop* 1994;105:506-11.
4. Atherton JD. The gingival response to orthodontic tooth movement. *Am J Orthod* 1970;58:179-86.
5. Tarnow DP, Magner AW, Fletcher P. The effect of the distance from the contact point to the crest of bone on the presence or absence of the interproximal dental papilla. *J Periodontol* 1992; 63:995-6.
6. Kokich VG. Esthetics: the orthodontic-periodontic restorative connection. *Semin Orthod* 1996;2:21-30.
7. Evian CI, Rosenberg ES. Retained interdental papilla procedure for maintaining anterior esthetics. *Compend Contin Educ Dent* 1985;6:58-64.
8. Jansen CE, Weisgold A. Presurgical treatment planning for the anterior single-tooth implant restoration. *Compend Contin Educ Dent* 1995;16:746-62.
9. Geylikman YB, Artun J, Leroux BG, Bloomquist D, Baab D, Ramsay DS. Effects of LeFort I osteotomy on human gingival and pulpal circulation. *Int J Oral Maxillofac Surg* 1995;24: 255-60.
10. Taylor RMS. Variation in form of human teeth: I. an anthropologic and forensic study of maxillary incisors. *J Dent Res* 1969; 48:5-16.