

The Role of Orthodontics as an Adjunct to Periodontal Therapy

Vincent G. Kokich



CHAPTER



CHAPTER OUTLINE

BENEFITS OF ORTHODONTICS FOR A PERIODONTAL PATIENT

PREORTHODONTIC OSSEOUS SURGERY

Osseous Craters

Three-Wall Intrabony Defects

ORTHODONTIC TREATMENT OF OSSEOUS DEFECTS

Hemiseptal Defects

Advanced Horizontal Bone Loss

Furcation Defects

Root Proximity

Fractured Teeth/Forced Eruption

Hopeless Teeth Maintained for

Orthodontic Anchorage

ORTHODONTIC TREATMENT OF GINGIVAL DISCREPANCIES

Uneven Gingival Margins

Significant Abrasion and Overeruption

Open Gingival Embrasures

SUMMARY

Orthodontic tooth movement may be a substantial benefit to the adult periorestorative patient. Many adults who seek routine restorative dentistry have problems with tooth malposition that compromise their ability to adequately clean and maintain their dentitions. If these individuals also are susceptible to periodontal disease, tooth malposition could be an exacerbating factor that could cause premature loss of specific teeth. Orthodontic appliances have become smaller, less noticeable, and easier to maintain during orthodontic therapy. Many adults are taking advantage of the opportunity to have their teeth aligned to improve the esthetics of their smiles. If these individuals also have underlying gingival or osseous periodontal defects, these defects often can be improved during orthodontic therapy if the orthodontist is aware of the situation and designs the appropriate tooth movement. In addition, implants have become a major part of the treatment plan for many adults with missing teeth. If adjacent teeth have drifted into edentulous spaces, orthodontics is often helpful to provide the ideal amount of space for implants and subsequent

restorations. This chapter shows the ways in which adjunctive orthodontic therapy can enhance the periodontal health and restorability of teeth.

BENEFITS OF ORTHODONTICS FOR A PERIODONTAL PATIENT

Orthodontic therapy can provide several benefits to the adult periodontal patient. The following six factors should be considered:

1. Aligning crowded or malposed maxillary or mandibular anterior teeth permits the adult patient better access to adequately clean all surfaces of their teeth. This could be a tremendous advantage for patients who are susceptible to periodontal bone loss or do not have the dexterity to adequately maintain their oral hygiene.
2. Vertical orthodontic tooth repositioning can improve certain types of osseous defects in periodontal patients. Often, the tooth movement eliminates the need for resective osseous surgery.

3. Orthodontic treatment can improve the esthetic relationship of the maxillary gingival margin levels before restorative dentistry. Aligning the gingival margins orthodontically avoids gingival recontouring, which potentially could require bone removal and exposure of the roots of the teeth.
4. The *fourth* benefit of orthodontics is for the patient who has suffered a severe fracture of a maxillary anterior tooth, which requires forced eruption to permit adequate restoration of the root. In this situation, erupting the root allows the crown preparation to have sufficient resistance form and retention for the final restoration.
5. Orthodontic treatment allows open gingival embrasures to be corrected to regain lost papilla. If these open gingival embrasures are located in the maxillary anterior region, they can be unaesthetic. In most patients, these areas can be corrected with a combination of orthodontic root movement, tooth reshaping, and/or restoration.
6. Orthodontic treatment could improve adjacent tooth position before implant placement or tooth replacement. This is especially true for the patient who has been missing teeth for several years and has drifting and tipping of the adjacent dentition.

PREORTHODONTIC OSSEOUS SURGERY

The extent of the osseous surgery depends on the type of defect (i.e., crater, hemiseptal defect, three-wall defect, and/or furcation lesion). The prudent clinician knows which defects can be improved with orthodontic treatment and which defects require preorthodontic, periodontal, surgical intervention.

Osseous Craters

An osseous crater is an interproximal, two-wall defect that does not improve with orthodontic treatment. Some shallow craters (i.e., 4- to 5-mm pocket) may be maintainable nonsurgically during orthodontic treatment. However, if surgical correction is necessary, this type of osseous lesion can easily be eliminated by reshaping the defect^{12,15} and reducing the pocket depth (Fig. 53-1) (see Chapter 62). This in turn enhances the ability to maintain these interproximal areas during orthodontic treatment. The need for surgery is based on the patient's response to initial root planing, the patient's periodontal resistance, the location of the defect, and the predictability of maintaining defects nonsurgically while the patient is wearing orthodontic appliances.

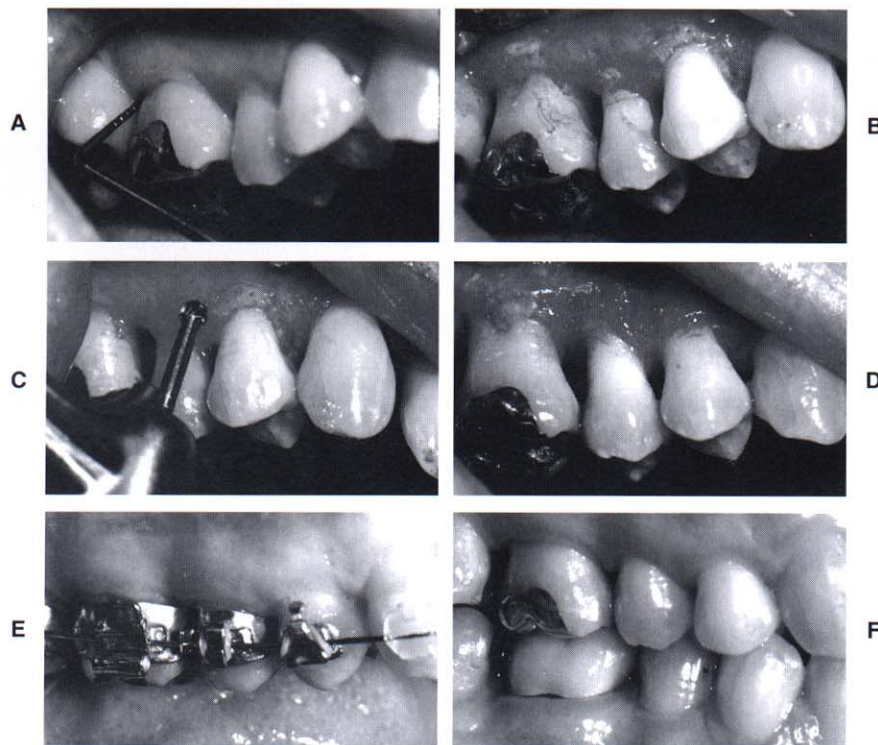


Fig. 53-1 This patient had a 6-mm probing defect distal to the maxillary right first molar (**A**). When this area was flapped (**B**), a cratering defect was apparent. Osseous surgery was used to alter the bony architecture on the buccal and lingual to eliminate the defect (**C and D**). After 6 weeks, the probing pocket defect had been reduced to 3 mm, and orthodontic appliances were placed on the teeth (**E**). By eliminating the crater before orthodontics, the patient could maintain the area during and after orthodontics (**F**).

Three-Wall Intrabony Defects

Three-wall defects are amenable to pocket reduction with regenerative periodontal therapy.¹ Bone grafts using either autogenous bone from the surgical site or allografts along with the use of resorbable membranes have been successful in filling three-wall defects.¹⁴ If the result of periodontal therapy is stable (Fig. 53-2) 3 to 6 months after periodontal surgery, orthodontic treatment may be initiated.

ORTHODONTIC TREATMENT OF OSSEOUS DEFECTS

Hemiseptal Defects

Hemiseptal defects are one- or two-wall osseous defects that often are found around mesially tipped teeth (Fig. 53-3) or teeth that have supererupted (Fig. 53-4). Usually, these defects can be eliminated with the appropriate orthodontic treatment. In the case of the tipped tooth, uprighting^{2,5} and eruption of the tooth levels the bony defect. If the tooth is supererupted, intrusion and leveling of the adjacent cementoenamel junctions can help level the osseous defect.

It is imperative that periodontal inflammation be controlled before orthodontic treatment. This usually can be achieved with initial debridement and rarely re-

quires any preorthodontic surgery. After the completion of orthodontic treatment, these teeth should be stabilized for at least 6 months and reassessed periodontally. Often, the pocket has been reduced or eliminated and no further periodontal treatment is needed. It would be injudicious to perform preorthodontic osseous corrective surgery in such lesions if orthodontics is part of the overall treatment plan.

In the periodontally healthy patient, orthodontic brackets are positioned on the posterior teeth relative to the marginal ridges and cusps. However, some adult patients may have marginal ridge discrepancies caused by uneven tooth eruption. When marginal ridge discrepancies are encountered, the decision as to where to place the bracket or band is not determined by the anatomy of the tooth. In these situations, it is important to assess these teeth radiographically to determine the interproximal bone level.

If the bone level is oriented in the same direction as the marginal ridge discrepancy, then leveling the marginal ridges will level the bone. However, if the bone level is flat between adjacent teeth (see Fig. 53-4) and the marginal ridges are at significantly different levels, correction of the marginal ridge discrepancy orthodontically produces a hemiseptal defect in the bone. This could cause a periodontal pocket between the two teeth.

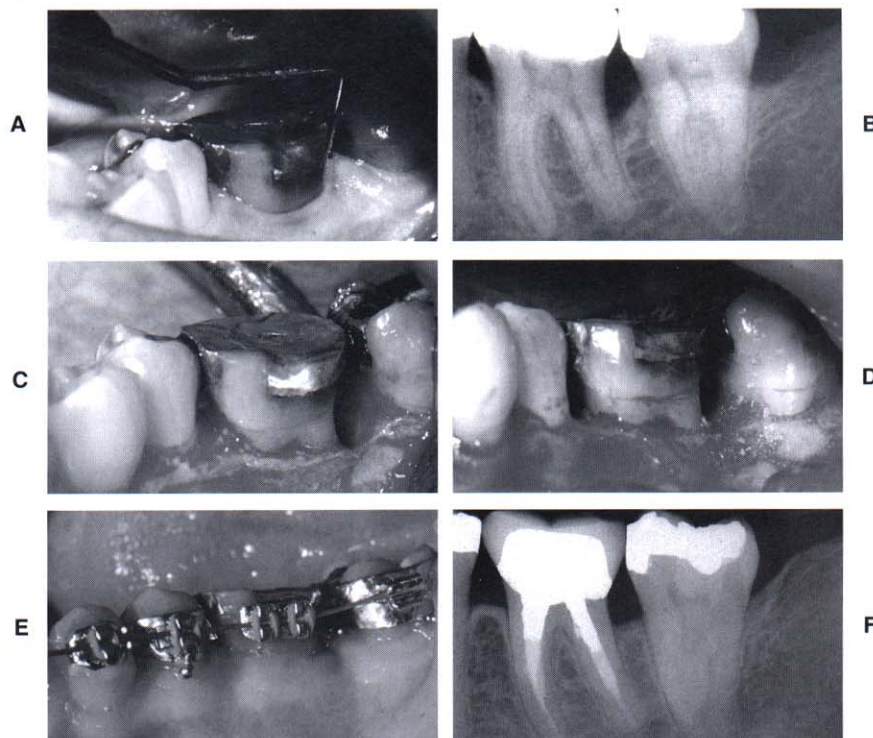


Fig. 53-2 This patient had a significant periodontal pocket (A) distal to the mandibular right first molar. A periapical radiograph (B) confirmed the osseous defect. A flap was elevated (C), revealing a deep, three-wall osseous defect. Freeze-dried bone (D) was placed in the defect 6 months after the bone graft. Orthodontic treatment was initiated (E). The final periapical radiograph shows that the preorthodontic bone graft helped regenerate bone and eliminate the defect distal to the molar (F).

If the bone is flat and a marginal ridge discrepancy is present, the orthodontist should not level the marginal ridges orthodontically. In these situations, it may be necessary to equilibrate the crown of the tooth (see Fig. 53-4). For some patients, the latter technique may require endodontic therapy and restoration of the tooth because of the required amount of reduction of the length of the crown. This approach is acceptable if the treatment results in a more favorable bone contour between the teeth.

In some patients, a discrepancy may exist between both the marginal ridges and the bony levels between two teeth. However, these discrepancies may not be of equal magnitude. In these patients, orthodontic leveling of the bone may still leave a discrepancy in the marginal ridges (Fig. 53-5). In these situations, the crowns of the teeth should not be used as a guide for completing orthodontic therapy. The bone should be leveled orthodontically and any remaining discrepancies between the marginal ridges should be equilibrated. This method produces the best occlusal result and improves the periodontal health.

During orthodontic treatment, when teeth are being extruded to level hemiseptal defects, the patient should be monitored regularly. Initially, the hemiseptal defect has a greater sulcular depth and is more difficult for the

patient to clean. As the defect is ameliorated through tooth extrusion, interproximal cleaning becomes easier. The patient should be recalled every 2 to 3 months during the leveling process to control inflammation in the interproximal region.

Advanced Horizontal Bone Loss

After orthodontic treatment has been planned, one of the most important factors that determine the outcome of orthodontic therapy is the location of the bands and brackets on the teeth. In a periodontally healthy individual, the position of the brackets is usually determined by the anatomy of the crowns of the teeth. Anterior brackets should be positioned relative to the incisal edges. Posterior bands or brackets are positioned relative to the marginal ridges. If the incisal edges and marginal ridges are at the correct level, the cementoenamel junction (CEJ) will also be at the same level. This relationship creates a flat, bony contour between the teeth. However, if a patient has underlying periodontal problems and significant alveolar bone loss around certain teeth, using the anatomy of the crown to determine bracket placement is not appropriate (Fig. 53-6).

In a patient with advanced horizontal bone loss, the bone level may have receded several millimeters from

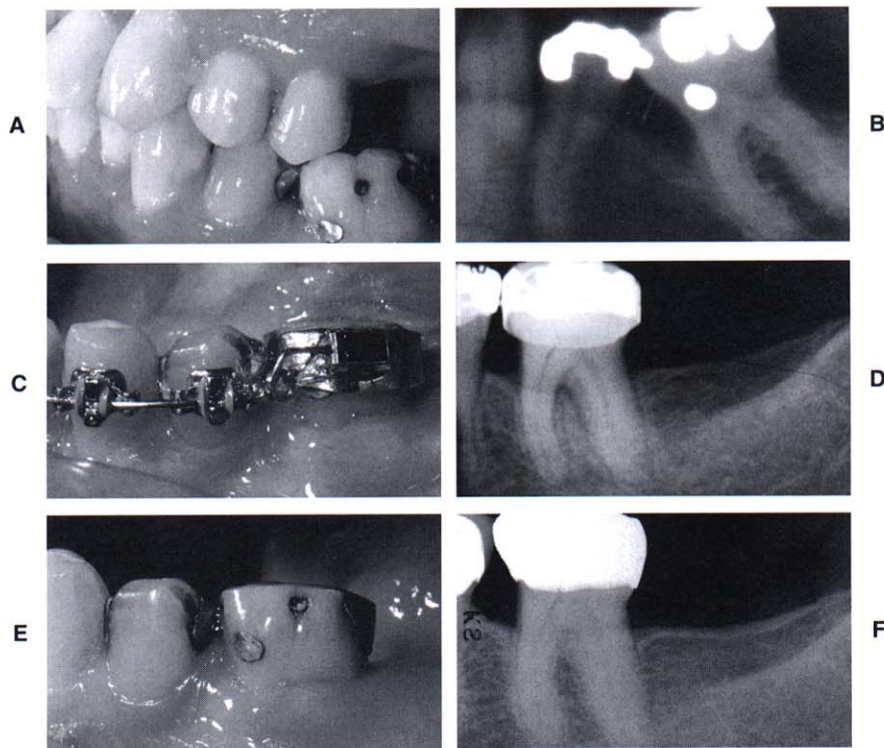


Fig. 53-3 This patient was missing the mandibular left second premolar, and the first molar had tipped mesially (A). A pretreatment periapical radiograph (B) revealed a significant hemiseptal osseous defect on the mesial of the molar. To eliminate the defect, the molar was erupted and the occlusal surface was equilibrated (C). The eruption was stopped when the bone defect was leveled (D). The posttreatment intraoral photograph (E) and periapical radiograph (F) show that the periodontal health had been improved by correcting the hemiseptal defect orthodontically.

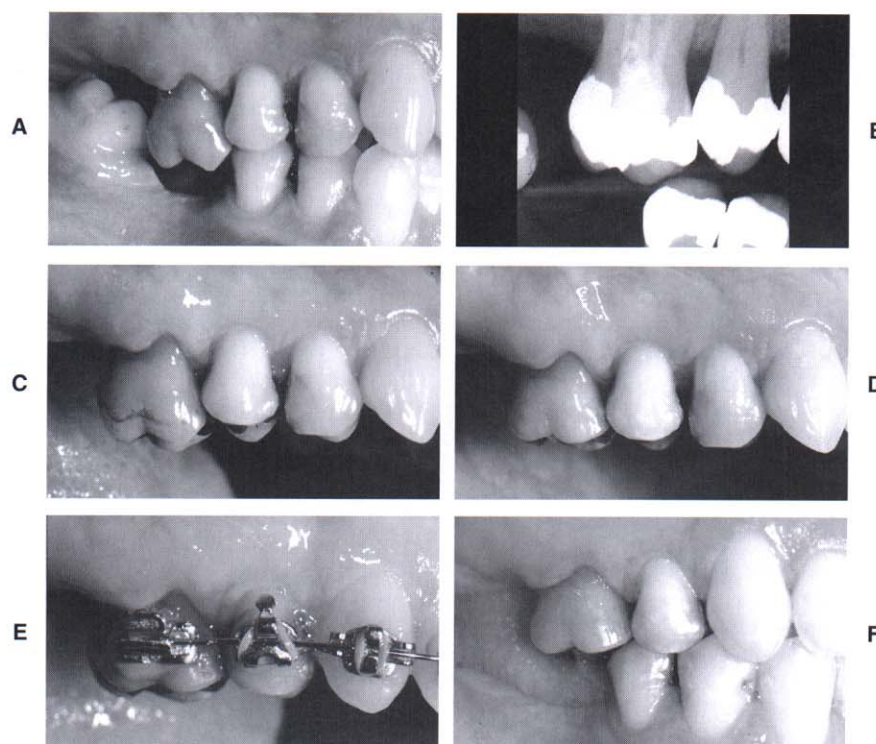


Fig. 53-4 This patient showed overeruption of the maxillary right first molar and a marginal ridge defect between the second premolar and first molar (**A**). A pretreatment periapical radiograph (**B**) showed that the interproximal bone was flat. To avoid creating a hemiseptal defect, the occlusal surface of the first molar was equilibrated (**C and D**) and the malocclusion was corrected orthodontically (**E and F**).

the CEJ. As this occurs, the crown-to-root ratio becomes less favorable. By aligning the crowns of the teeth, the clinician may perpetuate tooth mobility by maintaining an unfavorable crown-to-root ratio. In addition, by aligning the crowns of the teeth and disregarding the bone level, significant bone discrepancies occur between healthy and periodontally diseased roots. This could require periodontal surgery to ameliorate the discrepancies.

Many of these problems can be corrected by using the bone level as a guide to position the brackets on the teeth (see Fig. 53-6). In these situations, the crowns of the teeth may require considerable equilibration. If the tooth is vital, the equilibration should be performed gradually to allow the pulp to form secondary dentin and insulate the tooth during the equilibration process. The goal of equilibration and creative bracket placement is to provide a more favorable bony architecture as well as a more favorable crown-to-root ratio. In some of these patients, the periodontal defects that were apparent initially may not require periodontal surgery after orthodontic treatment.

Furcation Defects

Furcation defects can be classified as incipient (Class I), moderate (Class II), or advanced (Class III). These lesions

require special attention in the patient undergoing orthodontic treatment. Often, the molars require bands with tubes and other attachments that impede the patient's access to the buccal furcation for home care and instrumentation at the time of recall.

Furcation lesions require special consideration because they are the most difficult lesions to maintain and can worsen during orthodontic therapy. These patients need to be maintained on a 2- to 3-month recall schedule. Detailed instrumentation of these furcations helps minimize further periodontal breakdown.

If a patient with a Class III furcation defect will be undergoing orthodontic treatment, a possible method for treating the furcation is to eliminate it by hemisecting the crown and root of the tooth (Fig. 53-7). However, this procedure requires endodontic, periodontal, and restorative treatment. If the patient will be undergoing orthodontic treatment, it is advisable to perform the orthodontic treatment first. This is especially true if the roots of the teeth will not be moved apart. In these patients, the molar to be hemisected remains intact during orthodontics (see Fig. 53-7). This patient would require 2- or 3-month recall visits to ensure that the furcation defect does not lose bone during orthodontic treatment. Keeping the tooth intact during the orthodontics simplifies the concentration of tooth movement for the orthodontist. After orthodontics, endodontic therapy is

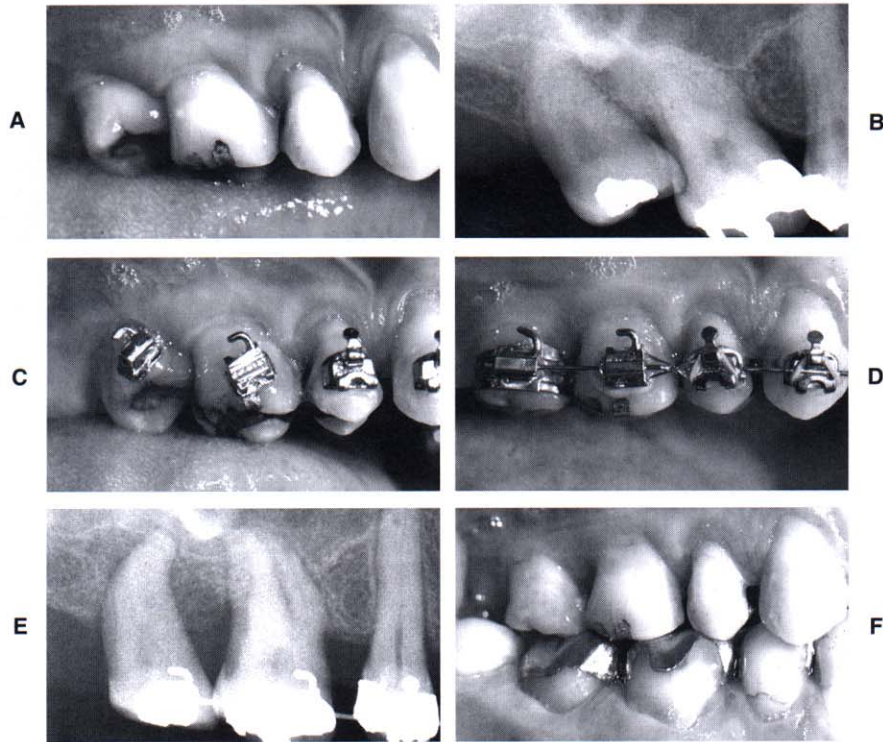


Fig. 53-5 Before orthodontic treatment, this patient had significant mesial tipping of the maxillary right first and second molars, causing marginal ridge discrepancies (**A**). The tipping produced root proximity between the molars (**B**). To eliminate the root proximity, the brackets were placed perpendicular to the long axis of the teeth (**C**). This method of bracket placement facilitated root alignment and elimination of the root proximity as well as leveling of the marginal ridge discrepancies (**D, E, and F**).

required (followed by periodontal surgery) to divide the tooth.

In some patients requiring hemisection of a mandibular molar with a Class III furcation, pushing the roots apart during orthodontic treatment may be advantageous (Fig. 53-8). If the hemisected molar will be used as an abutment for a bridge after orthodontics, moving the roots apart orthodontically permits a favorable restoration and splinting across the adjacent edentulous spaces.

In the latter situation, hemisection, endodontic therapy, and periodontal surgery must be completed before the start of orthodontic treatment. After these procedures have been completed, bands or brackets can be placed on the root fragments and coil springs used to separate the roots. The amount of separation is determined by the size of the adjacent edentulous spaces and the occlusion in the opposing arch. About 7 or 8 mm may be created between the roots of the hemisected molar. This process eliminates the original furcation problem and allows the patient to clean the area with greater efficiency.

In some molars with Class III furcation defects, the tooth may have short roots, advanced bone loss, fused roots, or other problems that prevent hemisection and crowning of the remaining roots. In these patients (Fig. 53-9), extracting the root with a furcation defect and placing an implant may be more advisable.¹¹ If this type

of plan has been adopted, the timing of the extraction and placement of the implant can occur at any time relative to the orthodontic treatment. In some situations, the implant could be used as an anchor to facilitate pre-restorative orthodontic treatment (see Fig. 53-9).

The implant must remain embedded in bone for 4 to 6 months after placement before it can be loaded as an orthodontic anchor. It must be placed precisely so that it not only provides an anchor for tooth movement but also may be used as an eventual abutment for a crown or fixed bridge. If the implant will not be used as an anchor for orthodontic movement, it may be placed after the orthodontic treatment has been completed. Considerations regarding timing are determined by the restorative treatment plan.

Root Proximity

When roots of posterior teeth are in close proximity, the ability to maintain periodontal health and accessibility for restoration of adjacent teeth may be compromised.⁴ However, if the patient were undergoing orthodontic therapy, the roots can be moved apart and bone will be formed between the adjacent roots (see Fig. 53-5). This opens the embrasure beneath the tooth contact, provides additional bone support, and enhances the patient's access to the interproximal region for hygiene.

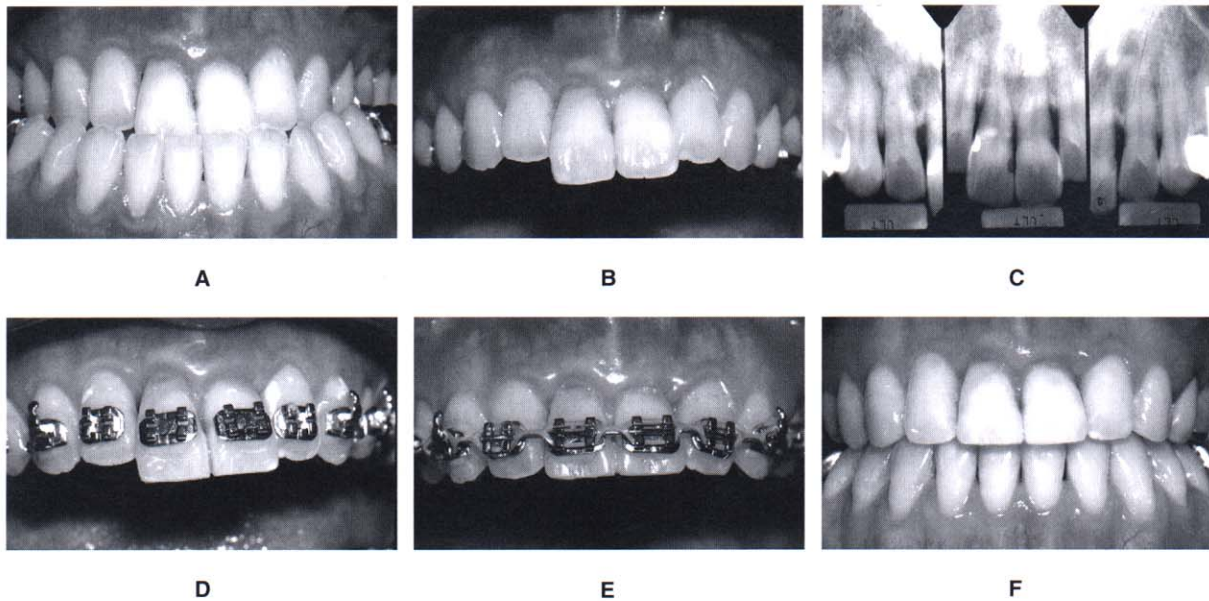


Fig. 53-6 Before orthodontic treatment, this patient had a significant Class III malocclusion (A). The maxillary central incisors had overerupted (B) relative to the occlusal plane. A pretreatment periapical radiograph (C) showed that significant horizontal bone loss had occurred. To avoid creating a vertical periodontal defect by intruding the central incisors, the brackets were placed to maintain the bone height (D). The incisal edges of the centrals were equilibrated (E), and the orthodontic treatment was completed without intruding the incisors (F).

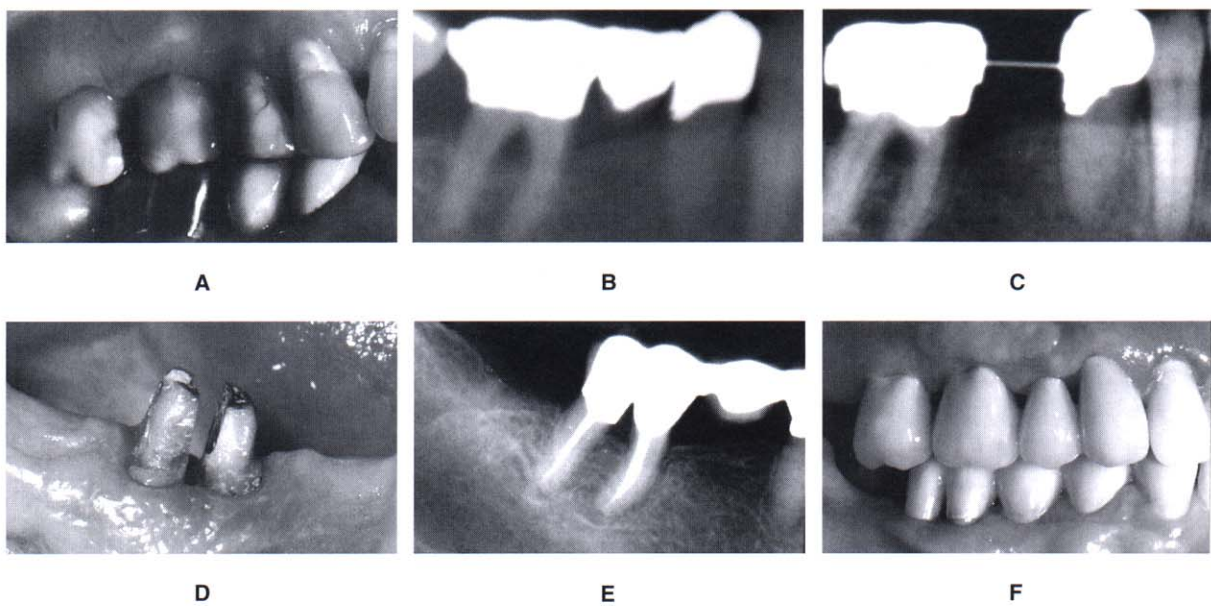


Fig. 53-7 This patient had a Class III furcation defect before orthodontic treatment (A and B). Orthodontic treatment was performed (C), and the furcation defect was maintained by the periodontist on 2-month recalls until after orthodontic treatment. After appliance removal, the tooth was hemisected (D), and the roots were restored, and splinted together (E). The final periapical radiograph (F) shows that the furcation defect has been eliminated by hemisecting and restoring the two root fragments.

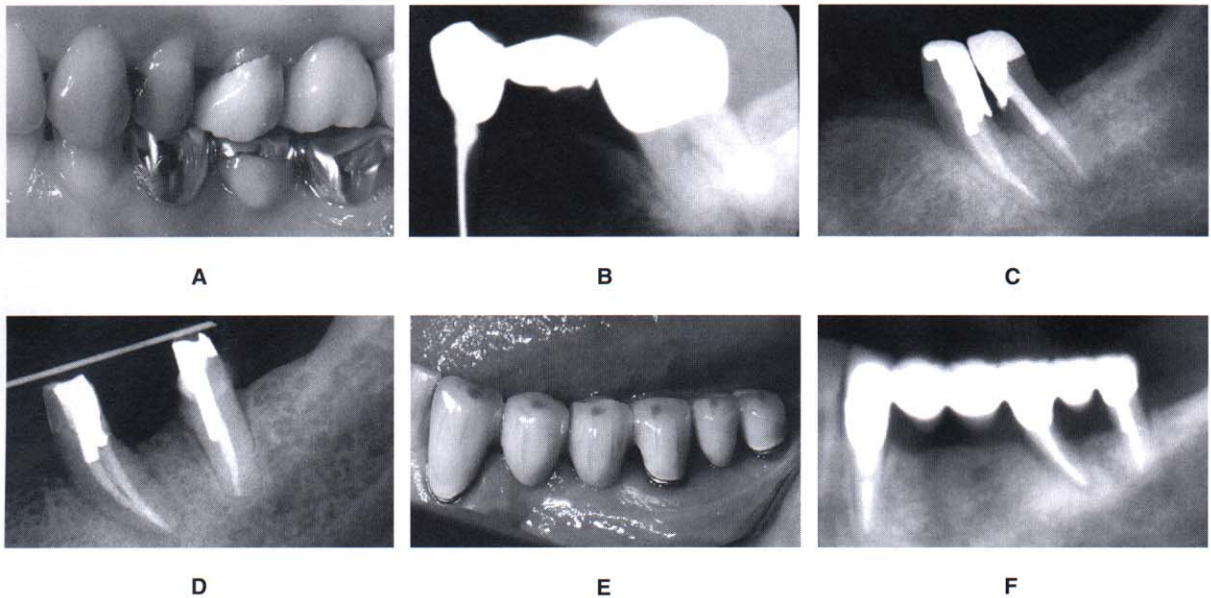


Fig. 53-8 Before orthodontic treatment, this patient had a Class III furcation defect in the mandibular left second molar (**A and B**). Because the patient had an edentulous space mesial to the molar, the tooth was hemisected (**C**), and the root fragments were separated orthodontically (**D**). After orthodontic treatment, the root fragments were used as abutments to stabilize a multiunit posterior bridge (**E and F**).

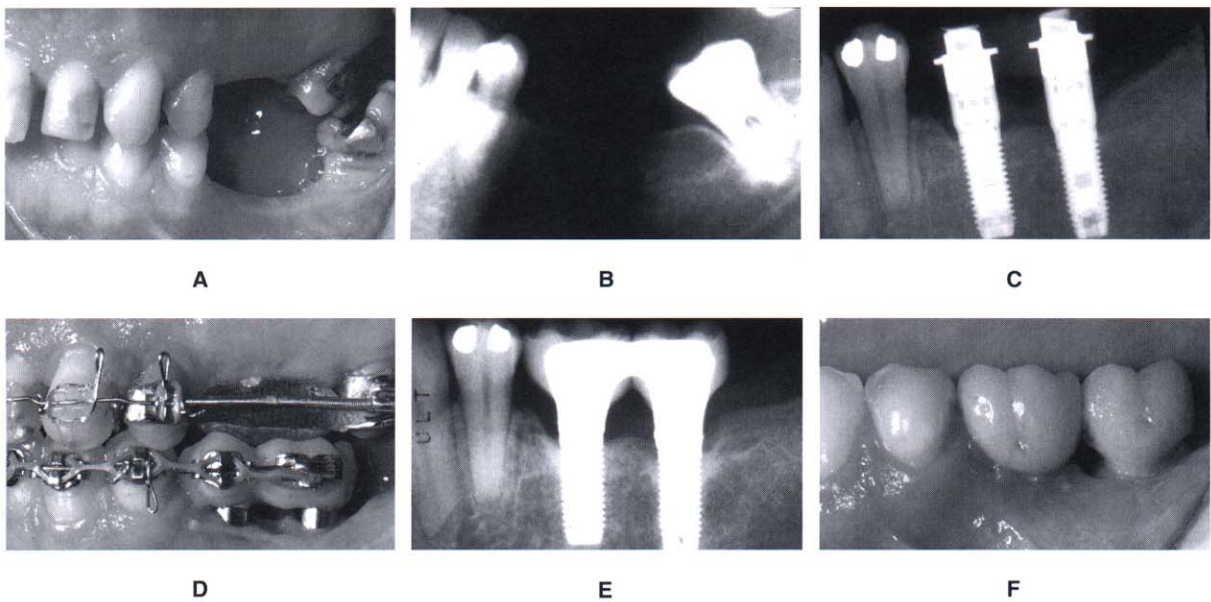


Fig. 53-9 This patient was missing several teeth in the mandibular left posterior quadrant (**A**). The mandibular left third molar had a Class III furcation defect and short roots (**B**). The third molar was extracted and two implants were placed in the mandibular left posterior quadrant (**C**). The implants were used as anchors to facilitate orthodontic treatment (**D**) and help reestablish the left posterior occlusion (**E and F**).

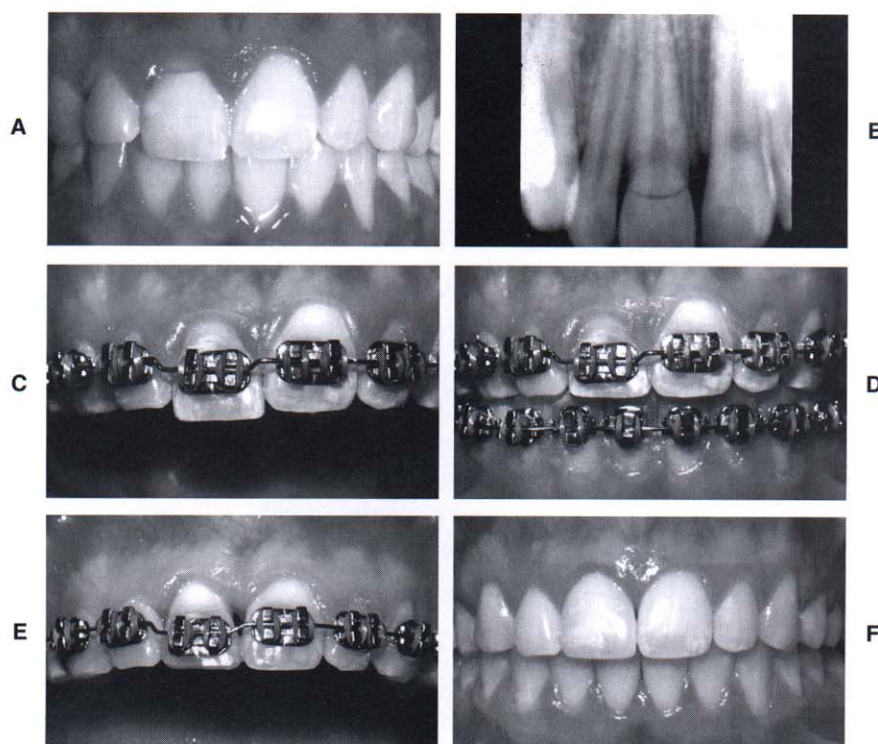


Fig. 53-10 This patient had a severe fracture of the maxillary right central incisor (**A**) that extended apical to the level of the alveolar crest on the lingual (**B**). To restore the tooth adequately and avoid impinging on the periodontium, the fractured root was extruded 4 mm (**C**). As the tooth erupted, the gingival margin followed the tooth (**D**). Gingival surgery was required to lengthen the crown of the central incisor (**E**) so that the final restoration had sufficient ferrule for resistance and retention and the appropriate gingival margin relationship with the adjacent central incisor (**F**).

This generally improves the periodontal health of this area.

If orthodontic treatment will be used to move roots apart, this plan must be known before bracket placement. It is advantageous to place the brackets so that the orthodontic movement to separate the roots will begin with the initial archwires (see Fig. 53-5). Therefore brackets must be placed obliquely to facilitate this process. To determine the progress of orthodontic root separation, radiographs are needed to monitor the status. Generally, 2 to 3 mm of root separation provides adequate bone and embrasure space to improve periodontal health. During this time, the patient should be maintained to ensure that a favorable bone response occurs as the roots are moved apart. In addition, these patients need occasional occlusal adjustment to recontour the crown because the roots are moving apart. As this occurs, the crowns may develop an unusual occlusal contact with the opposing arch. This should be equilibrated to improve the occlusion.

Fractured Teeth/Forced Eruption

Occasionally, children and adolescents may fall and accidentally injure their anterior teeth. If the injuries are minor and result in small fractures of enamel, these can be

restored with light-cured composite or porcelain veneers. However, in some situations, the fracture may extend beneath the level of the gingival margin and terminate at the level of the alveolar ridge (Fig. 53-10). In these situations, restoration of the fractured crown is impossible because the tooth preparation would extend to the level of the bone. This overextension of the crown margin could result in an invasion of the biologic width of the tooth and cause persistent inflammation of the marginal gingiva. It may be beneficial in such cases to erupt the fractured root out of the bone and move the fracture margin coronally so that it can be properly restored.⁷ However, if the fracture extends too far apically, it may be better to extract the tooth and replace it with an implant or bridge. Six criteria determine whether the tooth should be forcibly erupted or extracted.

1. *Root length:* Is the root long enough so that a one-to-one crown-root ratio will be preserved after the root has been erupted? To determine the answer to this question, the clinician must know how far to erupt the root. If a tooth fracture extends to the level of the bone, it must be erupted 4 mm. The first 2.5 mm moves the fracture margin far enough away from the bone to prevent a biologic width problem. The other 1.5 mm provides the proper amount of ferrule for

adequate resistance form of the crown preparation. Therefore if the root is fractured to the bone level and must be erupted 4 mm, the periapical radiograph must be evaluated (see Fig. 53-10) and 4 mm subtracted from the end of the fractured tooth root. The length of the residual root should be compared with the length of the eventual crown on this tooth. The root-to-crown ratio should be about 1:1. If the root-to-crown ratio is less than this amount, there may be too little root remaining in the bone for stability. In the latter situation, it may be prudent to extract the root and place a bridge or implant.

2. **Root form:** The shape of the root should be broad and nontapering, rather than thin and tapered. A thin, tapered root provides a narrower cervical region after the tooth has been erupted 4 mm. This could compromise the esthetic appearance of the final restoration. The internal root form is also important. If the root canal is wide, the distance between the external root surface and root canal filling will be narrow. In these situations, the walls of the crown preparation are thin, which could result in early fracture of the restored root. The root canal should not be more than one third of the overall width of the root. In this way, the root could still provide adequate strength for the final restoration.
3. **Level of the fracture:** If the entire crown is fractured 2 to 3 mm apical to the level of the alveolar bone, it is difficult, if not impossible, to attach to the root to erupt it.
4. **Relative importance of the tooth:** If the patient were 70 years of age and both adjacent teeth had prosthetic crowns, then it could be more prudent to construct a fixed bridge. However, if the patient is 15 years of age and the adjacent teeth were unrestored, then forced eruption would be much more conservative and appropriate.
5. **Esthetics:** If the patient has a high lip line and displays 2 to 3 mm of gingiva when smiling, then any type of restoration in this area will be more obvious. In this situation, keeping the patient's own tooth would be much more esthetic than any type of implant or prosthetic replacement.
6. **Endo/perio prognosis:** If the tooth has a significant periodontal defect, it may not be possible to retain the root. In addition, if the tooth root has a vertical fracture, the prognosis would be poor and extraction of the tooth would be the proper course of therapy.

If all these factors are favorable, then forced eruption of the fractured root is indicated. The orthodontic mechanics necessary to erupt the tooth can vary from elastic traction to orthodontic banding and bracketing. If a large portion of the tooth is still present, then orthodontic bracketing is necessary. If the entire crown has fractured, leaving only the root, then elastic traction from a bonded bar may be possible. The root may be erupted rapidly or slowly. If the movement is performed rapidly, the alveolar bone will be left behind temporarily and a circumferential fibrotomy may be performed to prevent bone from following the erupted root. However, if the root is erupted slowly, the bone follows the tooth. In this situation, the

erupted root requires crown lengthening to expose the correct amount of tooth to create the proper ferrule, resistance form, and retention for the final restoration.

After the tooth root has been erupted, it must be stabilized to prevent it from intruding back into the alveolus. The reason for reintrusion is the orientation of the principal fibers of the periodontium. During forced eruption, the periodontal fibers become oriented obliquely and stretched as the root moves coronally. These fibers eventually reorient themselves after about 6 months. Before this occurs, the root can reintrude significantly. Therefore if this type of treatment is performed, an adequate period of stabilization is necessary to avoid significant relapse and reintrusion of the root.

As the root erupts, the gingiva move coronally with the tooth. As a result, the clinical crown length becomes shorter after extrusion (see Fig. 53-10). In addition, the gingival margin may be positioned more incisally than the adjacent teeth. In these situations, gingival surgery is necessary to create ideal gingival margin heights. The type of surgery varies depending on whether bone removal is necessary. If bone has followed the root during eruption, a flap is elevated and the appropriate amount of bone is removed to match the bone height of the adjacent teeth. If the bone level is flat between adjacent teeth, a simple excisional gingivectomy corrects the gingival margin discrepancy.

After gingival surgery, an open gingival embrasure may exist between the erupted root and adjacent teeth (see Fig. 53-10). The space occurs because the narrower root portion of the erupted tooth has been moved into the oral cavity. This space may be closed in two different ways. One method involves overcontouring of the replacement restoration. The other method involves reshaping of the crown of the tooth and movement of the root to close the space. This latter method often helps improve the overall shape of the final crown on the restored tooth.

Hopeless Teeth Maintained for Orthodontic Anchorage

Patients with advanced periodontal disease may have specific teeth diagnosed as hopeless, which would be extracted before orthodontics (Fig. 53-11). However, these teeth can be useful for orthodontic anchorage if the periodontal inflammation can be controlled. In moderate to advanced cases, some periodontal surgery may be indicated around a hopeless tooth. Flaps are reflected for debridement of the roots to control inflammation around the hopeless tooth during the orthodontic process. The important factor is to maintain the health of the bone around the adjacent teeth. Periodontal recall is imperative during the process.

After orthodontic treatment, there is a six-month period of stabilization before reevaluating the periodontal status. Occasionally, the hopeless tooth may be so improved after orthodontic treatment that it is retained. However, in most cases, the hopeless tooth requires extraction, especially if other restorations are planned in the segment. Again, these decisions require reevaluation by the clinician.

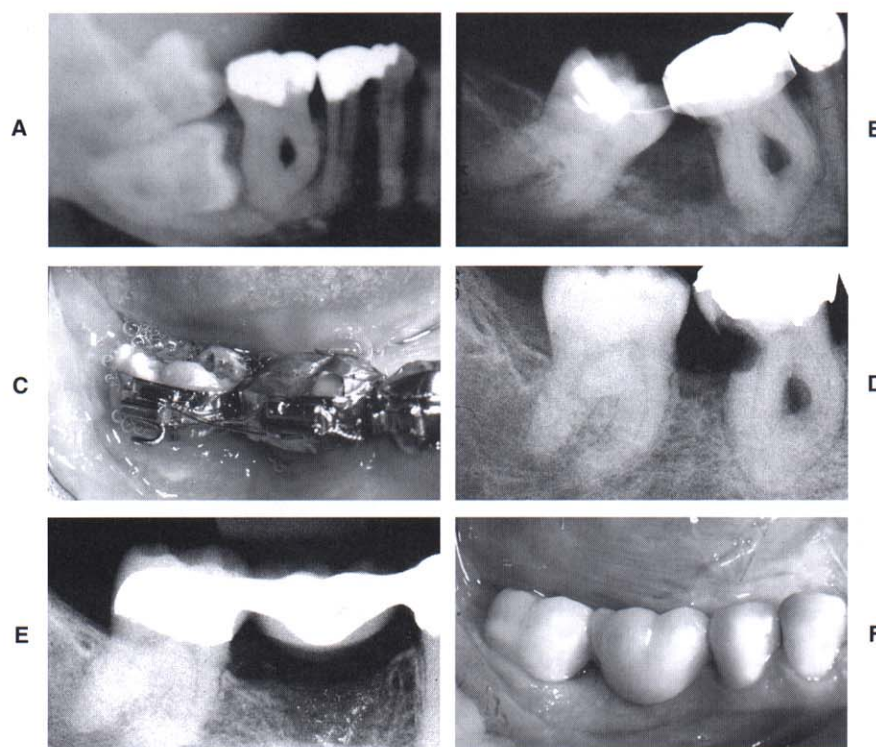


Fig. 53-11 This patient had an impacted mandibular right second molar (**A**). The mandibular right first molar was periodontally hopeless because of an advanced Class III furcation defect. The impacted second molar was extracted, but the first molar was maintained as an anchor to help upright the third molar orthodontically (**B, C, and D**). After orthodontic uprighting of the third molar, the first molar was extracted and a bridge was placed to restore the edentulous space (**E and F**).

ORTHODONTIC TREATMENT OF GINGIVAL DISCREPANCIES

Uneven Gingival Margins

The relationship of the gingival margins of the six maxillary anterior teeth plays an important role in the esthetic appearance of the crowns. Four factors contribute to ideal gingival form.

1. The gingival margins of the two central incisors should be at the same level.
2. The gingival margins of the central incisors should be positioned more apically than the lateral incisors and at the same level as the canines.¹³
3. The contour of the labial gingival margins should mimic the CEJs of the teeth.
4. A papilla should exist between each tooth, and the height of the tip of the papilla is usually halfway between the incisal edge and the labial gingival height of contour over the center of each anterior tooth. Therefore the gingival papilla occupies half of the interproximal contact, and the adjacent teeth form the other half of the contact.

However, some patients may have gingival margin discrepancies between adjacent teeth (Fig. 53-12). These discrepancies could be caused by abrasion of the incisal

edges or delayed migration of the gingival margins. When gingival margin discrepancies are present, the proper solution for the problem must be determined: orthodontic movement to reposition the gingival margins or surgical correction of gingival margin discrepancies.

To make the correct decision, it is necessary to evaluate four criteria. First, the relationship between the gingival margin of the maxillary central incisors and the patient's lip line should be assessed when the patient smiles. If a gingival margin discrepancy is present but the discrepancy is not exposed, it does not require correction.

If a gingival margin discrepancy is apparent, the second step is to evaluate the labial sulcular depth over the two central incisors. If the shorter tooth has a deeper sulcus, excisional gingivectomy may be appropriate to move the gingival margin of the shorter tooth apically. However, if the sulcular depths of the short and long incisors are equivalent, gingival surgery does not correct the problem.

The third step is to evaluate the relationship between the shortest central incisor and the adjacent lateral incisors. If the shortest central is still longer than the lateral incisors, the other possibility is to extrude the longer central incisor and equilibrate the incisal edge. This moves the gingival margin coronally and eliminates the gingival margin discrepancy. However, if the shortest central is shorter than the laterals, this technique would

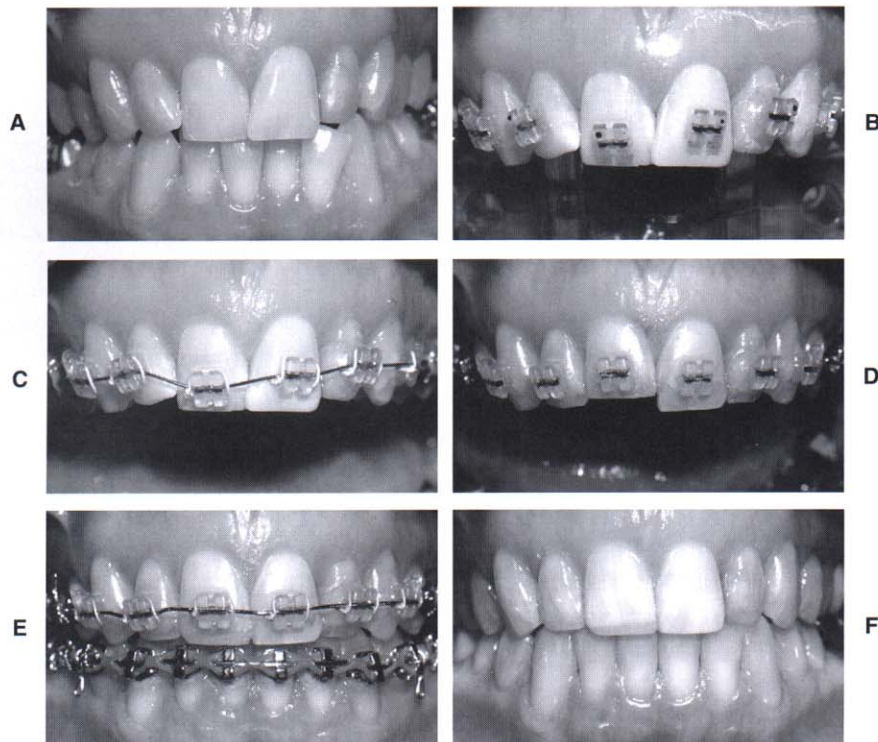


Fig. 53-12 This patient had a protrusive bruxing habit that had resulted in abrasion and overeruption of the maxillary right central incisor (**A**). The objective was to level the gingival margins during orthodontic therapy. Although gingival surgery was a possibility, the labial sulcular depth of the maxillary right central incisor was only 1 mm, and the CEJ was located at the bottom of the sulcus. Therefore the best solution involved positioning the orthodontic brackets to facilitate intrusion of the right central incisor (**B, C, and D**). This permitted the restorative dentist to restore the portion of the tooth that the patient had abraded (**E**), resulting in the correct gingival margin levels and crown lengths at the end of treatment (**F**).

produce an unaesthetic relationship between the gingival margins of the central and lateral incisors.

The fourth step is to determine whether the incisal edges have been abraded. This is best accomplished by evaluating the teeth from an incisal perspective. If one incisal edge is thicker labiolingually than the adjacent tooth, this may indicate that it has been abraded and the tooth has overerupted. In such cases, the best method of correcting the gingival margin discrepancy is to intrude the short central incisor (see Fig. 53-12). This method moves the gingival margin apically and permits restoration of the incisal edges.^{3,6,8-10} The intrusion should be accomplished at least 6 months before appliance removal. This allows reorientation of the principal fibers of the periodontium and avoids reextrusion of the central incisor(s) after appliance removal.

Significant Abrasion and Overeruption

Occasionally, patients have destructive dental habits such as a protrusive bruxing habit that could result in significant wear of the maxillary and mandibular incisors and compensatory overeruption of these teeth (Fig. 53-13). The restoration of these abraded teeth is often impossible because of the lack of crown length to

achieve adequate retention and resistance form for the crown preparations. Two options are available. One option is extensive crown lengthening by elevating a flap, removing sufficient bone, and apically positioning the flap to expose adequate tooth length for crown preparation. However, this type of procedure is contraindicated in the patient with short tapered roots because it could adversely affect the final root to crown ratio and potentially open gingival embrasures between the anterior teeth.

The other option for improving the restorability of these short abraded teeth is to orthodontically intrude the teeth and move the gingival margins apically (see Fig. 53-13). It is possible to intrude up to four maxillary incisors by using the posterior teeth as anchorage during the intrusion process. This process is accomplished by placing the orthodontic brackets as close to the incisal edges of the maxillary incisors as possible. The brackets are placed in their normal position on the canines and remaining posterior teeth. The patient's posterior occlusion resists the eruption of the posterior teeth, and the incisors gradually intrude and move the gingival margins and the crowns apically. This creates the restorative space necessary to temporarily restore the incisal edges of these teeth and then eventually place the final crowns.

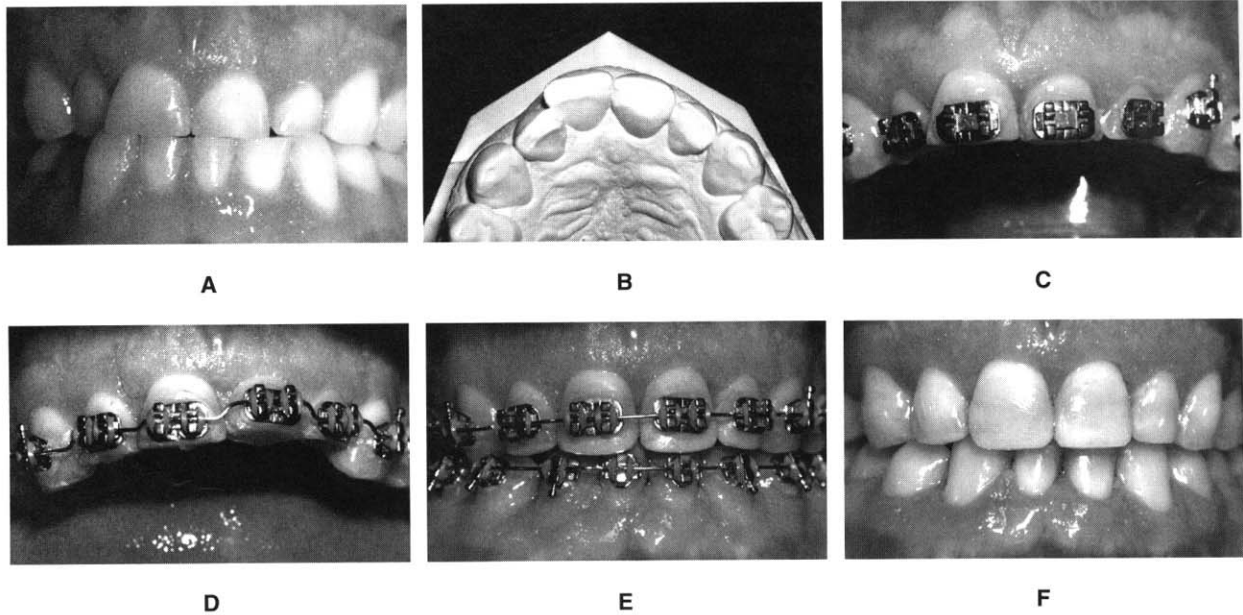


Fig. 53-13 This patient had a protrusive bruxing habit that had caused severe abrasion of the maxillary anterior teeth, resulting in the loss of over half of the crown length of the incisors (**A and B**). Two possible options existed for gaining crown length to restore the incisors. One possibility was an apically positioned flap with osseous recontouring, which would expose the roots of the teeth. The less destructive option was to intrude the four incisors orthodontically, level the gingival margins (**C and D**), and allow the dentist to restore the abraded incisal edges (**E and F**). The orthodontic option was clearly successful and desirable in this patient.

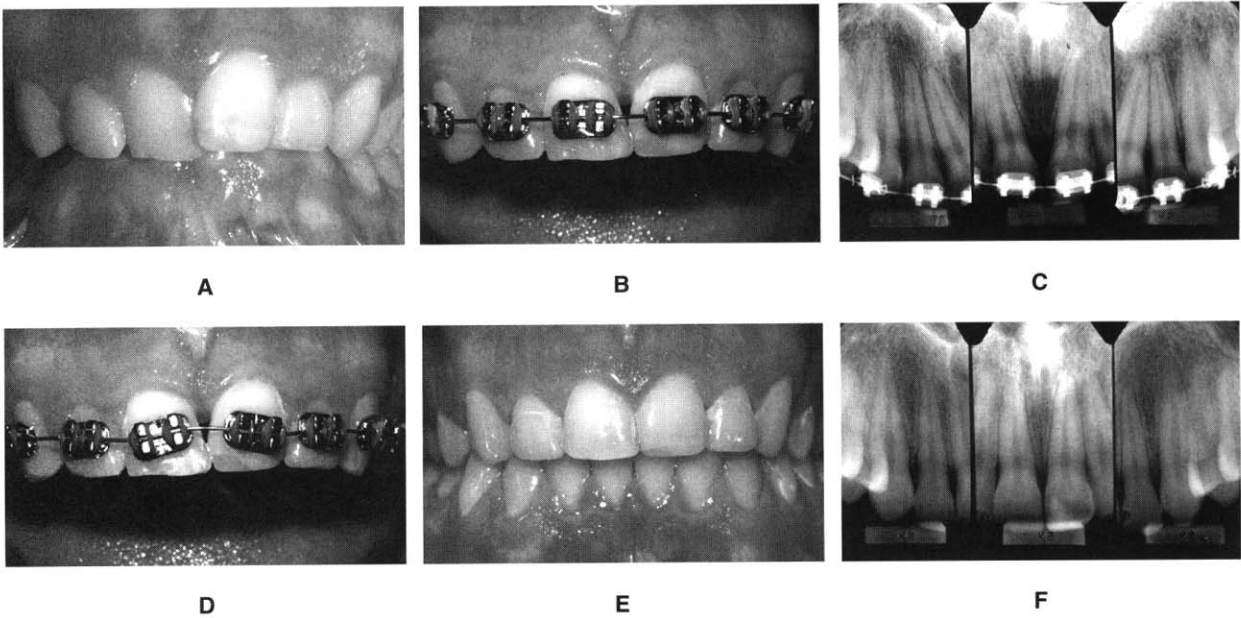


Fig. 53-14 This patient initially had overlapped maxillary central incisors (**A**), and after initial orthodontic alignment of the teeth, an open gingival embrasure appeared between the centrals (**B**). A radiograph showed that the open embrasure was caused by divergence of the central incisor roots (**C**). To correct the problem, the central incisor brackets were repositioned (**D**), and the roots were moved together. This required restoration of the incisal edges after orthodontics (**E**) because these teeth had worn unevenly before orthodontic therapy. As the roots were paralleled (**F**), the tooth contact moved gingivally and the papilla moved incisally, resulting in the elimination of the open gingival embrasure.

When abraded teeth are significantly intruded, it is necessary to hold these teeth for at least 6 months in the intruded position with either the orthodontic brackets, archwires, or both, or some type of bonded retainer. The principal fibers of the periodontium must accommodate to the new intruded position, a process that could take a minimum of 6 months in most adult patients. Orthodontic intrusion of severely abraded and overerupted teeth is usually a distinct advantage over periodontal crown lengthening unless the patient has extremely long and broad roots or has had extensive horizontal periodontal bone loss.

Open Gingival Embrasures

The presence of a papilla between the maxillary central incisors is a key esthetic factor in any individual. Occasionally, adults have open gingival embrasures or lack gingival papillae between their central incisors. These unaesthetic areas are often difficult to resolve with periodontal therapy. However, orthodontic treatment can correct many of these open gingival embrasures. This open space is usually due to one of three causes: tooth shape, root angulation, or periodontal bone loss.⁹

The interproximal contact between the maxillary central incisors consists of two parts. One portion is the

tooth contact, and the other is the papilla. The ratio of papilla to contact is 1:1. Half of the space is occupied by papilla, and half is formed by the tooth contact. If the patient has an open embrasure, the first aspect that must be evaluated is whether the problem is due to the papilla or the tooth contact. If the papilla is the problem, then the cause is usually a lack of bone support due to an underlying periodontal problem.

In some situations, a deficient papilla can be improved with orthodontic treatment. By closing open contacts, the interproximal gingiva can be squeezed and moved incisally. This type of movement may help create a more esthetic papilla between two teeth despite alveolar bone loss. Another possibility is to erupt adjacent teeth when the interproximal bone level is positioned apically.

Most open embrasures between the central incisors are due to problems with tooth contact. The first step in the diagnosis of this problem is to evaluate a periapical radiograph of the central incisors. If the root angulation is divergent, then the brackets should be repositioned so the root position can be corrected (Fig. 53-14). In these situations, the incisal edges may be uneven and require restoration with either composite or porcelain restorations. If the periapical radiograph shows that the roots are in their correct relationship, then the open gingival embrasure is due to a triangular tooth shape (Fig. 53-15).

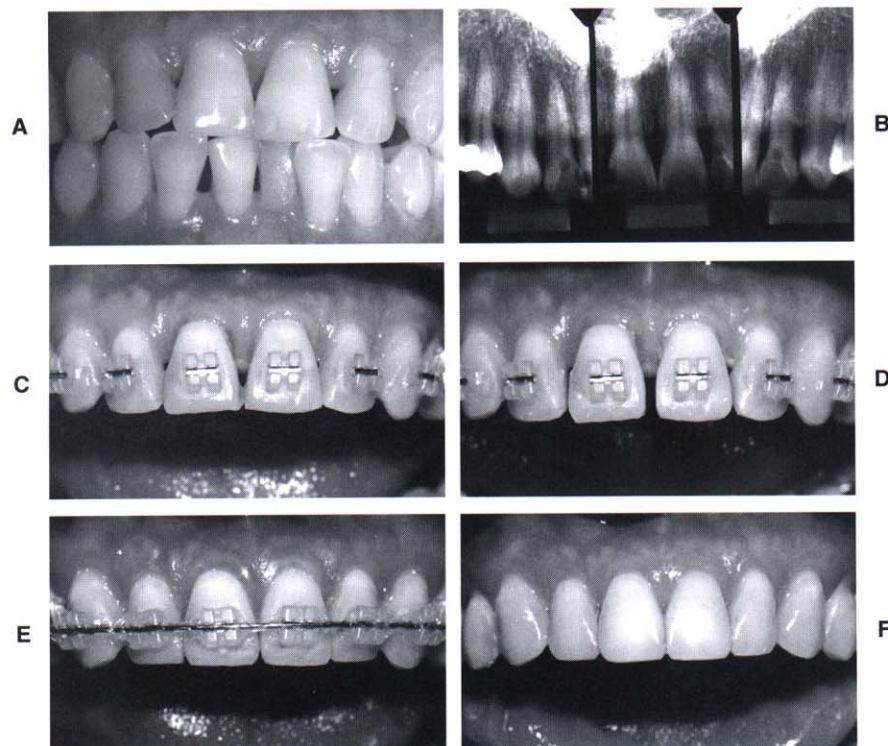


Fig. 53-15 This patient initially had triangular-shaped central incisors (**A and B**), which produced an open gingival embrasure after orthodontic alignment (**C**). Because the roots of the central incisors were parallel with one another, the appropriate solution for the open gingival embrasure was to recontour the mesial surfaces of the central incisors (**D**). As the diastema was closed (**E**), the tooth contact moved gingivally and the papilla moved incisally, resulting in the elimination of the open gingival embrasure (**F**).

If the shape of the tooth is the problem, two solutions are possible. One possibility is to restore the open gingival embrasure. The other option is to reshape the tooth by flattening the incisal contact and closing the space (see Fig. 53-15). This results in lengthening of the contact until it meets the papilla. In addition, if the embrasure space is large, closing the space squeezes the papilla between the central incisors. This helps create a 1:1 ratio between the contact and papilla and restores uniformity to the heights between the midline and adjacent papillae.

SUMMARY

This chapter has discussed and illustrated the benefits of integrating orthodontics and periodontics in the management of adult patients with underlying periodontal defects. The key to treating these types of patients is communication and proper diagnosis before orthodontic therapy as well as continued dialogue during orthodontic treatment. Not all periodontal problems are treated in the same way. This chapter has provided a framework for the integration of orthodontics to solve periodontal problems.

REFERENCES

1. Becker W, Becker BE: Treatment of mandibular 3-wall intrabony defects by flap debridement and expanded polytetrafluoroethylene barrier membranes. Long-term evaluation of 32 treated patients. *J Periodontol* 1993; 64:1138.
2. Brown IA: The effect of orthodontic therapy on certain types of periodontal defects. I. Clinical findings. *J Periodontol* 1973; 44:742.
3. Chiche G, Kokich V, Caudill R: Diagnosis and treatment planning of esthetic problems. In: Pinault A, Chiche G (eds): *Esthetics in Fixed Prosthodontics*. Chicago, Quintessence, 1994.
4. Gould MSE, Picton DCA: The relation between irregularities of the teeth and periodontal disease. *Br Dent J* 1966; 121:21.
5. Ingber J: Forced eruption: Part I. A method of treating isolated one and two wall infrabony osseous defects; rationale and case report. *J Periodontol* 1974; 45:199.
6. Kokich V: Enhancing restorative, esthetic and periodontal results with orthodontic therapy. In: Schluger S, Youdelis R, Page R, et al (eds): *Periodontal Therapy*. Philadelphia, Lea & Febiger, 1990.
7. Kokich V, Nappen D, Shapiro P: Gingival contour and clinical crown length: Their effects on the esthetic appearance of maxillary anterior teeth. *Am J Orthod* 1984; 86:89.
8. Kokich V: Anterior dental esthetics: An orthodontic perspective. I. Crown length. *J Esthet Dent* 1993; 5:19.
9. Kokich V: Esthetics and vertical tooth position: The orthodontic possibilities. *Compendium Cont Ed Dent* 1997; 18:1225.
10. Kokich V: Esthetics: The orthodontic-periodontic-restorative connection. *Semin Orthod* 1996; 2:21.
11. Kramer GM: Surgical alternatives in regenerative therapy of the periodontium. *Int J Periodont Rest Dent* 1992; 12:11.
12. Ochslein C, Ross S: A re-evaluation of osseous surgery. *Dent Clin North Am* 1969; 13:87.
13. Rufenacht C: Structural esthetic rules. In: Rufenacht C (ed): *Fundamental of Esthetics*. Chicago, Quintessence, 1990.
14. Schallhorn R, McClain P: Combined osseous composite grafting, root conditioning and guided tissue regeneration. *Int J Periodont Rest Dent* 1988; 8:9.
15. Schluger S: Osseous resection: A basic principle in periodontal surgery. *Oral Surg* 1949; 2:316.